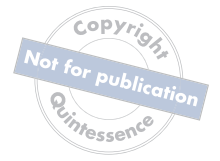



PRF in Facial Esthetics



Copyright
Not for publication
Quintessence

PRF IN FACIAL ESTHETICS

CATHERINE DAVIES, MBBCh, MBA

Private Practice Specializing in Facial Esthetics
Johannesburg, South Africa

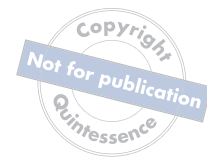RICHARD J. MIRON, DDS, BMSc, MSc, PhD, Dr med dent

Group Leader, The Miron Research Lab
Lead Educator, Advanced PRF Education
Venice, Florida



QUINTESSENCE PUBLISHING

Berlin | Chicago | Tokyo
Barcelona | London | Milan | Mexico City | Moscow | Paris | Prague | Seoul | Warsaw
Beijing | Istanbul | Sao Paulo | Zagreb



Library of Congress Cataloging-in-Publication Data

Names: Davies, Catherine, author. | Miron, Richard J. (Richard John), 1983- author.

Title: PRF in facial esthetics / Catherine Davies, Richard J. Miron.

Other titles: Platelet-rich fibrin in facial esthetics

Description: Batavia, IL : Quintessence Publishing Co, Inc, [2020] |

Includes bibliographical references and index. | Summary: "This book gathered numerous experts across many fields to collectively provide information on leading esthetic PRF therapies to expand treatment possibilities"-- Provided by publisher.

Identifiers: LCCN 2020009383 | ISBN 9780867159578 (hardcover)

Subjects: MESH: Face | Cosmetic Techniques | Fibrin--therapeutic use | Platelet-Rich Fibrin | Skin Aging | Rejuvenation | Esthetics, Dental

Classification: LCC RD119 | NLM WE 705 | DDC 617.9/52--dc23

LC record available at <https://lccn.loc.gov/2020009383>



© 2020 Quintessence Publishing Co, Inc

Quintessence Publishing Co, Inc
411 N Raddant Road
Batavia, IL 60510
www.quintpub.com

5 4 3 2 1

All rights reserved. This book or any part thereof may not be reproduced, stored in a retrieval system, or transmitted in any form or by any means, electronic, mechanical, photocopying, or otherwise, without prior written permission of the publisher.

Editor: Leah Huffman

Design: Sue Zubek

Production: Angelina Schmelter

Printed in USA

To Dr David Koski

When I moved to the United States 3 years ago, somehow you convinced me to think BIG. You took time out of your schedule to mentor me, volunteered many of your hours freely to support our education programs, and have been supportive beyond my comprehension. You called me Lebron when I didn't understand. You taught me to "scale" when I knew only science. And you provided endless advice on topics I never considered relevant. I never expected to find such a wonderful role model and mentor, all calmly behind the scenes. You never asked for recognition. I have no words to express my gratitude and wanted to somehow show my appreciation. I therefore dedicate this book to you, Dr Koski. This one is for you, big guy! —RJM

Contents /



Preface *viii*
Acknowledgments *ix*
Contributors *x*

1 / Introduction to Facial Esthetics and PRF 1

Richard J. Miron and Catherine Davies

2 / Facial Anatomy, Skin Biology, and the Effects of Aging 9

Catherine Davies and Richard J. Miron

3 / Photography in Facial Esthetics 27

Walter Rozen, Richard J. Miron, and Catherine Davies

4 / Consultation for the Facial Esthetic Patient 43

Richard J. Miron and Catherine Davies

5 / Consultation for the Hair Loss Patient 63

Alan J. Bauman, Catherine Davies, and Richard J. Miron

6 / Use of Platelet-Rich Fibrin in Facial Esthetics 79

Richard J. Miron, Yufeng Zhang, Ana Paz, Masako Fujioka-Kobayashi, and Catherine Davies

- 7 / Biology of Microneedling** 99
Erin Anderson, Nichole Kramer, Richard J. Miron, Ana Paz, and Catherine Davies
- 8 / Injection Techniques with Platelet-Rich Fibrin** 123
Catherine Davies, Ana Paz, Alireza Panahpour, Ana Cristina, and Richard J. Miron
- 9 / Hair Regeneration with Platelet-Rich Fibrin** 165
Catherine Davies and Richard J. Miron
- 10 / Lasers in Facial Esthetics** 175
Ana Paz, Harvey Shiffman, Miguel Stanley, Catherine Davies, and Richard J. Miron
- 11 / Skin Care Products and Their Effect on Aging Skin** 201
Geir Håvard Kvalheim, Catherine Davies, and Richard J. Miron
- 12 / Future Trends in Esthetic Medicine** 217
Carlos Fernando de Almeida Barros Mourão, Delia Tuttle, Ruth Delli Carpini, Scott Delboccio, Richard J. Miron, and Catherine Davies
- Index 230

Preface /



Facial esthetics has become one of the fastest-growing industries in the world. The esthetic demand for patients worldwide has never been higher, leading to this multibillion-dollar, booming industry. As the field continues to evolve, it is important that all medical practitioners are able to provide solid, evidence-based procedures while minimizing complications. Platelet concentrates have long been utilized in regenerative medicine, and over the years, the removal of anticoagulants has further improved their safety and effectiveness. Today, platelet-rich fibrin (PRF) has nearly replaced platelet-rich plasma in many fields of medicine and has gradually made its way into the medical esthetic arena. Furthermore, its use has been combined with other leading therapies to expand treatment possibilities. As trends continue to support minimally invasive esthetic procedures, it is clear that both the beginner as well as the advanced practitioner seek convenient, safe, and effective therapies.

This textbook is a first of its kind and an introduction to PRF in facial esthetics. The book was a true joy to put together, as many international experts in various fields of medicine have tremendously improved the quality of the final chapters. It has been a privilege to collaborate with basic scientists, the developers and clinician-scientists of microneedling, leading experts in laser therapy and low-level laser therapy, experts in photography, as well as plastic surgeons and hair restorative surgeons. This book is truly unique in that it gathered numerous experts across many fields with the ultimate goal of collectively providing as much knowledge on this topic as possible. We are therefore thrilled to present the first edition of our textbook, *PRF in Facial Esthetics*, and we look forward to your future feedback.



Acknowledgments

We greatly acknowledge the tremendous contributions of our coauthors. Each of your specific expertise has been greatly valuable, and what a privilege to continue to work with each of you. The field will certainly continue to progress, and we sincerely enjoy our collaborations with each of you.

We equally want to thank Quintessence Publishing for their trust, commitment, and devotion to this project. Thank you to Bryn Grisham (Director of Book Publications), Leah Huffman (Senior Editor and Deputy Editorial Director), Angelina Schmelter (Senior Digital & Print Production Specialist), and William Hartman (Executive Vice President & Director). The quality work at Quintessence Publishing and the attention to detail regarding the preparation of this manuscript are truly special.

To the team at KVM Publishing who originally designed and provided some of the anatomical illustrations in this book, thank you. In particular, we thank Gerhard Sattler and Uliana Gout for laying the groundwork with their fantastic book on facial fillers.

To Advanced PRF Education at prfedu.com and all of its staff members, including Erin Anderson and Nichole Kramer from Dermapen, thank you for making teaching and education a top priority filled with exciting new challenges and ongoing learning experiences.

From Catherine Davies

I would like to express special thanks and gratitude to my amazing family—Paco, Zahra, Cuba, and Lila—for putting up with all the long working hours this year.

I would also like to thank Dr Richard Miron for his belief in me and for his invaluable guidance and advice during the writing of this book.

From Richard J. Miron

To my parents and family: Your unconditional love and support during this past year never goes unnoticed. Thank you for everything!

To Dr Catherine Davies: It has been a true joy and pleasure to work with you. Your bubbly personality and easy-to-understand teaching style is enlightening and seems to perfectly blend with my serious and rigorous scientific approach. I've enjoyed every moment of it—let's keep going!

To Leah Huffman: How we managed three books together in 1 year is not something I could ever have imagined. Thank you endlessly for being dedicated, passionate, punctual, and simply the most outstanding and prolific editor!



Contributors /

Erin Anderson

Master Aesthetician
AO Surgical Arts
Salt Lake City, Utah

Director of Education
Dermapen

Alan J. Bauman, MD

Private Practice Specializing in Hair Transplant Surgery
Boca Raton, Florida

Ana Cristina, DDS, MSc

Private Practice Specializing in Facial Esthetics,
Implantology, and Oral Maxillofacial Surgery
São Paulo, Brazil

Catherine Davies, MBBCh, MBA

Private Practice Specializing in Facial Esthetics
Johannesburg, South Africa

Scott Delboccio, DMD

Private Practice
Naples, Florida

Ruth Delli Carpini, DMD

Private Practice Specializing in Cosmetic Dentistry
and Facial Esthetics
Milan, Italy

Masako Fujioka-Kobayashi, DDS, PhD

Research Associate
Department of Cranio-Maxillofacial Surgery
University Hospital of Bern
University of Bern
Bern, Switzerland

Nichole Kramer

Medical Aesthetician and Clinical Manager
Utah Body and Soul
Holladay, Utah

Co-director of Education
Dermapen

Geir Håvard Kvalheim

Founder of Čuvget
Tromsø, Norway

**Richard J. Miron, DDS, BMSc, MSc, PhD,
Dr med dent**

Group Leader, The Miron Research Lab
Lead Educator, Advanced PRF Education
Venice, Florida

**Carlos Fernando de Almeida Barros
Mourão, DDS, MSc, PhD**

Private Practice
San Pedro, California

Alireza Panahpour, DDS

Private Practice Specializing in Cosmetic Dentistry
Los Angeles, California

Ana Paz, DDS, MS

Private Practice
Lisbon, Portugal

Walter Rozen

Professional Photographer
Venice, Florida

Harvey Shiffman, DDS

Private Practice Specializing in Laser Therapy
Boynton Beach, Florida

Miguel Stanley, DDS

Private Practice
Lisbon, Portugal

Delia Tuttle, DDS, MD

Private Practice
Lake Elsinore, California

Yufeng Zhang, MD, DDS, PhD

Professor, Department of Dental Implantology
School of Stomatology
Wuhan University
Wuhan, China

Copyright
Not for publication
Quintessence

1 /

INTRODUCTION TO FACIAL ESTHETICS AND PRF

Richard J. Miron
Catherine Davies

Facial esthetics has become one of the fastest-growing industries in the world. While originally a number of minimally invasive procedures were utilized effectively in facial esthetics (including Botox [Allergan], hyaluronic acids, and polydioxanone [PDO] threads), more recently platelet concentrates have gained momentum because of their more natural regenerative approach. The main advantage of platelet concentrates is that they offer a safe, easy-to-obtain, and completely immune-biocompatible method for the *healing or regeneration* of aging skin. This differs significantly from previous modalities that aim to act as *fillers* or *paralyzers*, which initiate a foreign body reaction once placed within living tissue. As the population continues to age and becomes more concerned with their esthetic appearances, more and more clinicians and practitioners wish to offer patients a natural approach with platelet concentrates and more specifically platelet-rich fibrin (PRF). As trends continue to support minimally invasive esthetic procedures, it is clear that both beginner as well as advanced practitioners seek convenient, safe, and effective therapies. Platelet-rich plasma (PRP) was the first platelet concentrate utilized in facial esthetics because of its supraphysiologic accumulation of platelets and their respective growth factors, known stimulators of tissue regeneration. However, one of its main limitations is its incorporation of anticoagulants, known inhibitors of wound healing. Today, with advancements in centrifugation protocols and centrifugation tube characteristics, it has become possible to utilize a liquid injectable PRF without incorporation of anticoagulants. This formulation has been studied and utilized extensively in various fields of medicine and has become increasingly popular in facial esthetics. This textbook provides a first-of-its-kind introduction to the use of PRF in facial esthetics.

Aging of the Skin

Aging of the skin is an inevitable process that gradually occurs as we get older^{1,2} (Fig 1-1). Several factors have been associated with this process, including both genetic and environmental factors.³ Exposure to sun, pollution, and various chemicals have been known to cause skin and/or DNA damage, speeding the aging process.³ A number of changes to the skin may occur as a result, including skin atrophy, telangiectasia, fine and deep wrinkles, yellowing (solar elastosis), and dyspigmentation.³ Furthermore, poor diet, lack of exercise, caffeine intake, smoking, and drug use are additional factors known to speed the aging process.⁴

One key element certainly important for overall health and particularly skin attractiveness is hydration. Dehydration of the skin may lead to epithelial cell apoptosis and flaky skin complexion. From this standpoint, skin dehydration is a major risk factor for skin aging, and many topical applications, including hyaluronic acid creams, are geared toward water retention as a modality to prevent dryness of the skin. Aging skin is also related to a number of obvious demarcations of the face (see chapter 2). Depressions in the corners of the mouth, cheeks, forehead, eyebrows, eyelids, and

nose are all associated with aging⁵ (Box 1-1; see Fig 1-1). Based on visible differences that occur with aging, a variety of treatment options have been proposed to favor a more youthful appearance, but hydration is a key feature.

As the body ages, it undergoes many changes that directly impact the physiology of human tissues, resulting in lower cellular activity.⁶ These changes include a loss in density, increases in fat storage, and lower production of collagen. A reduction in collagen synthesis as well as its associated increase in collagen degradation both have apparent disadvantages leading to a net loss of facial volume, resulting in skin folds and wrinkles⁷ (see chapter 2). Based on these changes associated with aging, several years ago it was proposed that platelet concentrates could be utilized in facial esthetics to improve collagen synthesis and restore facial volume.⁸⁻¹⁰ The main function of platelet concentrates is to increase recruitment and proliferation of cells and to further speed revascularization/blood flow toward defective areas. Many advancements have been made since the first-generation platelet concentrate—platelet-rich plasma (PRP). Several devices and isolation kits have since been fabricated based on the concept of isolating platelets for regenerative purposes,

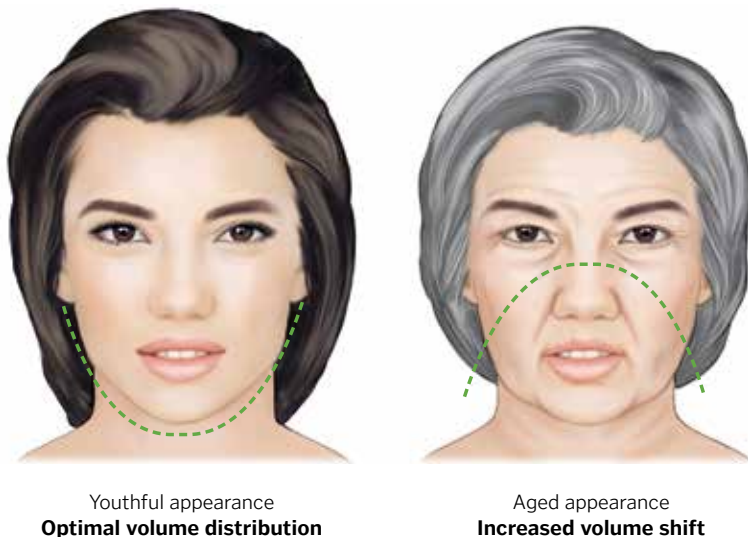


FIG 1-1

The process of skin aging. With age, facial features tend to sag, with a volume shift downward of facial tissues.

BOX 1-1**Progressive changes expected in normal aging**

- Corners of the mouth move inferiorly, resulting in a slight frown look
- Cheeks sag inferiorly, resulting in the appearance of jowls
- Tissue around the eyes sags inferiorly
- Eyelids (upper and lower) sag inferiorly
- Tissue of the forehead drifts inferiorly, creating wrinkles and dropping the eyebrows downward with flatter appearances
- Nose may elongate and the tip may regress inferiorly
- Nose may develop a small to pronounced dorsal hump
- Tip of the nose may enlarge and become bulbous
- Generalized wrinkling to the face naturally occurs

eliminating the inclusion of anticoagulants and speeding the preparation protocols. This second-generation platelet formulation, termed *platelet-rich fibrin* (PRF), has formed the basis for more than 600 scientific publications on the topic and has now extended into the field of facial esthetics. This textbook addresses this topic in detail and introduces the concept of PRF as a safer, more effective regenerative platelet concentrate that is 100% natural and thereby prevents a foreign body response.

Traditional Methods for Facial Rejuvenation

One of the first methods proposed for facial rejuvenation incorporated acupuncture.¹¹ This concept was derived based on accumulating evidence that trauma to the skin in the form of a needle and/or syringe, dermal roller, or more recently microneedling (see chapter 7) could induce slight tissue damage leading to new angiogenesis, growth factor release, and subsequent new tissue regeneration. This tissue regeneration resulted in a more youthful appearance.

Because of the popularity of such treatments in facial esthetics and rapidly increasing trends in

the field, more invasive techniques have also been proposed. These include facelifts, aggressive laser treatment modalities, and various grafting procedures.¹²⁻¹⁴ One of the advantages of platelet therapies is their ability to be used in combination with microneedling (see chapter 7), lasers (see chapter 10), plastic surgery (see chapter 12), and hair restoration (see chapter 9) simply to improve healing outcomes.

Traditional Biomaterials for Facial Rejuvenation

While various protocols and injectable materials have been proposed in facial esthetics, patients generally seek more natural regenerative approaches with the shortest possible downtime. In addition, medicine has gradually and naturally progressed toward more minimally invasive procedures. Today, many different agents and biomaterials can be utilized to accomplish this task, including Botox, fillers (eg, silicone, calcium hydroxyapatite, polymethyl methacrylate, hyaluronic acid products, hyaluronic acid + calcium hydroxyapatite, polylactic acid), various laser therapies at different wavelengths/intensities, and polydioxanone (PDO) threads.¹⁵⁻²¹ These products and modalities have been

BOX 1-2

Unesthetic features that can be treated or eliminated with esthetic medicine procedures

- Scars
- Skin laxity
- Wrinkles
- Moles
- Liver spots
- Excess fat
- Cellulite
- Unwanted hair
- Skin discoloration
- Spider veins

made popular by extensive marketing and celebrity endorsements and have been demonstrated to be successful in various esthetic procedures to improve cosmetic appearance (Box 1-2).

Importantly, however, these techniques heavily rely on normal protective mechanisms of the epidermis, which can be altered or disrupted following their use. The use of Botox, for example, has shown secondary effects that may cause a cascade of reactions with potential consequences.²² Botox causes temporary denervation and relaxation of muscles by preventing the release of the neurotransmitter acetylcholine at the peripheral nerve endings.²³ Clinicians generally recommend repeated injections every 6 months or so to maintain the facial appearance, but these injections may lead to secondary effects associated with an increased granular layer or thinning of the epidermis as a result of a foreign body reaction to this material.^{24,25} Other reported secondary effects include cases of muscle paresis including muscle weakness,



a

FIG 1-2

Esthetic medicine focuses on improving cosmetic appearance via a variety of procedures aimed at restoring the patient's youthful look. (a) PRF naturally regenerates tissues, resulting in a natural-looking outcome. (b) Dermal fillers, on the other hand, fill tissues unnaturally, resulting in a less natural-looking appearance. Full lips in women are often considered attractive and desirable in modern society, and lip augmentation with fillers is the traditional method by which to achieve that look.



b

brow ptosis, upper and/or lower eyelid ptosis, lateral arching of the eyebrow, double or blurred vision, loss or difficulty in voluntary eyelid closure, upper lip ptosis, uneven smile, lateral lip ptosis, lower lip flattening, orbicularis oris weakness, difficulty in chewing, dysphagia, altered voice pitch, and neck weakness. And dermal fillers have been associated with over 40 cases of blindness!

Despite the potential for negative outcomes, Botox and dermal fillers are generally considered safe and effective (Box 1-3). Nonetheless, such cases of blindness and ptosis are sure to create some fear within the community. Therefore, other materials (especially those with limited complications) are constantly being investigated as potential alternatives that do not bear significant secondary side effects. The goal of therapy with PRF is not to replace these previously utilized materials but simply to offer an additional and safer modality to the field that regenerates tissues naturally (Fig 1-2a) as opposed to filling or paralyzing tissues unnaturally (Fig 1-2b). PRF therapy therefore offers a natural regenerative approach with natural-looking outcomes (see Fig 1-2a). While each of the previously utilized materials offers its respective advantages and limitations (like any material), it is important to note that each is also foreign to the body and creates an additional inflammatory response when entering the body. These products have certainly demonstrated low patient morbidity and complication rates, but less invasive therapies offer a decreased risk of potential complications and a reduction in patient fear. This is often heavily favored by new patients wishing to enter their first facial esthetic regimen.

Esthetic Medicine

The field of esthetic medicine typically encompasses three specialties: (1) plastic surgery, (2) dermatology, and (3) reconstructive surgery. These specialties offer both surgical and nonsurgical esthetic procedures to improve cosmetic outcomes (Box 1-4), and these procedures can improve quality of life, psychologic well-being, and social function for many patients.

BOX 1-3

Safety of Botox and dermal fillers

These materials have been utilized in millions of patients with relatively few serious adverse effects. While there have been some negative case reports, medical use of Botox and fillers is generally considered safe and effective. Proper training and use of high-quality products (ie, approved materials) are recommended.

BOX 1-4

Procedures in esthetic medicine

Surgical

- Liposuction
- Facelift
- Breast implants
- Radiofrequency abrasion

Nonsurgical

- Mesotherapy
- Radiofrequency skin tightening
- Nonsurgical liposuction
- Chemical peel
- Laser treatment

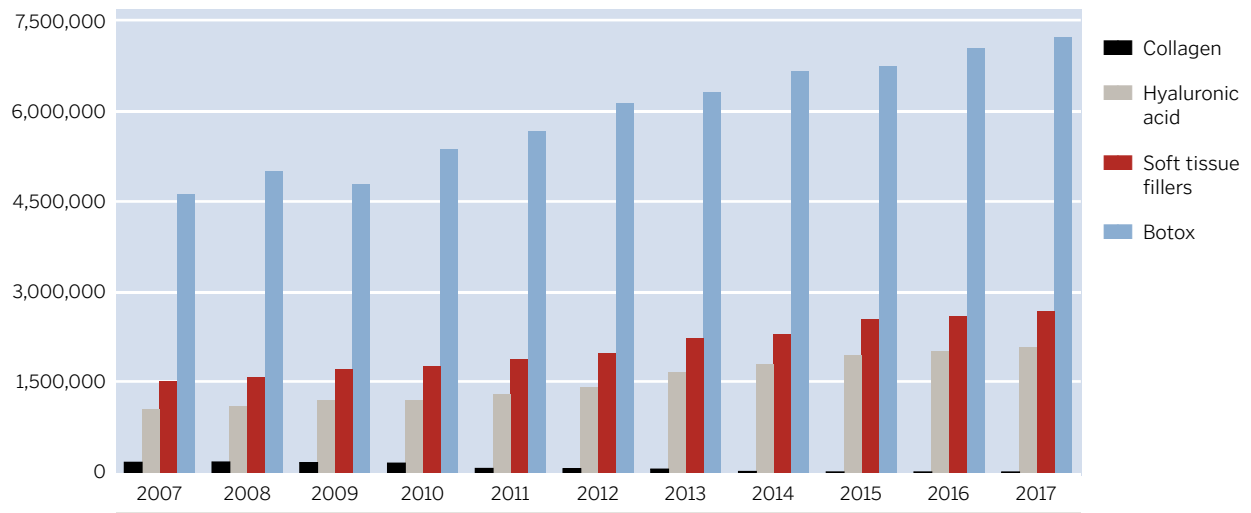


FIG 1-3

Number of minimally invasive procedures performed annually in the United States, a total of 16 million. (Adapted from the American Society of Plastic Surgeons.²⁶)

It is now estimated that roughly 16 million esthetic procedures are performed annually in the United States alone, as reported by the American Society of Plastic Surgeons²⁶ (Fig 1-3). Furthermore, reports have estimated that one billion people worldwide seek out solutions to help their facial and neck skin appear more youthful. This demand for facial esthetic procedures is only expected to further increase, as the skin care products market is valued at \$177 billion annually.

Therefore, the ability to offer a more natural, autologous concentrate of growth factors derived from

peripheral blood offers a very easy-to-obtain and low-cost method to regenerate facial tissues for patients. These less-invasive procedures have further become a norm in combination with microneedling, facial skin rejuvenation procedures, and hair restoration. Blood concentrates offer the ability to reach supraphysiologic doses of growth factors and cells responsible for the healing of various tissues using a natural healing approach.

References

1. Branchet M, Boisnic S, Frances C, Robert A. Skin thickness changes in normal aging skin. *Gerontology* 1990;36:28–35.
2. Helfrich YR, Sachs DL, Voorhees JJ. Overview of skin aging and photoaging. *Dermatology Nursing* 2008;20:177.
3. Herbig U, Ferreira M, Condell L, Carey D, Sedivy JM. Cellular senescence in aging primates. *Science* 2006;311:1257–1257.
4. Puizina-Ivi N. Skin aging. *Acta Dermatoven APA* 2008;17:47.
5. Friedman O. Changes associated with the aging face. *Facial Plast Surg Clin North Am* 2005;13:371–380.
6. Dimri GP, Lee X, Basile G, et al. A biomarker that identifies senescent human cells in culture and in aging skin in vivo. *Proc Natl Acad Sci U S A* 1995;92:9363–9367.
7. Lorencini M, Brohem CA, Dieamant GC, Zanchin NI, Maibach HI. Active ingredients against human epidermal aging. *Ageing Res Rev* 2014;15:100–115.
8. Kim DH, Je YJ, Kim CD, et al. Can platelet-rich plasma be used for skin rejuvenation? Evaluation of effects of platelet-rich plasma on human dermal fibroblast. *Ann Dermatol* 2011; 23:424–431.
9. Redaelli A. Face and neck revitalization with platelet-rich plasma (PRP): Clinical outcome in a series of 23 consecutively treated patients. *J Drugs Dermatol* 2010;9:466–472.
10. Na JI, Choi JW, Choi HR, et al. Rapid healing and reduced erythema after ablative fractional carbon dioxide laser resurfacing combined with the application of autologous platelet-rich plasma. *Dermatol Surg* 2011;37:463–468.
11. Barrett JB. Acupuncture and facial rejuvenation. *Aesthet Surg J* 2005;25:419–424.
12. Ramirez OM, Maillard GF, Musolas A. The extended subperiosteal face lift: A definitive soft-tissue remodeling for facial rejuvenation. *Plast Reconstr Surg* 1991;88:227–236.
13. Rohrich RJ, Ghavami A, Lemmon JA, Brown SA. The individualized component face lift: Developing a systematic approach to facial rejuvenation. *Plast Reconstr Surg* 2009;123:1050–1063.
14. El-Domyati M, Medhat W. Minimally invasive facial rejuvenation: Current concepts and future expectations. *Exp Rev Dermatol* 2013;8:565–580.
15. Cooke G. Effacing the face: Botox and the anarchic archive. *Body and Society* 2008;14:23–38.
16. Park MY, Ahn KY, Jung DS. Botulinum toxin type A treatment for contouring of the lower face. *Dermatol Surg* 2003; 29:477–483.
17. Carruthers JD, Glogau RG, Blitzer A. Advances in facial rejuvenation: Botulinum toxin type A, hyaluronic acid dermal fillers, and combination therapies—Consensus recommendations. *Plast Reconstr Surg* 2008;121(5 suppl):5S–30S.
18. Majid O. Clinical use of botulinum toxins in oral and maxillofacial surgery. *Int J Oral Maxillofac Surg* 2010;39:e197–e207.
19. Johl SS, Burgett RA. Dermal filler agents: A practical review. *Curr Opin Ophthalmol* 2006;17:471–479.
20. Wang L, Sun Y, Yang W, Lindo P, Singh BR. Type A botulinum neurotoxin complex proteins differentially modulate host response of neuronal cells. *Toxicon* 2014;82:52–60.
21. Allemann IB, Kaufman J. Fractional photothermolysis—An update. *Lasers Med Sci* 2010;25:137–144.
22. Dayan SH. Complications from toxins and fillers in the dermatology clinic: Recognition, prevention, and treatment. *Facial Plast Surg Clin North Am* 2013;21:663–673.
23. Sadick NS, Manhas-Bhutani S, Krueger N. A novel approach to structural facial volume replacement. *Aesthet Plast Surg* 2013;37:266–276.
24. El-Domyati M, Attia SK, El-Sawy AE, et al. The use of botulinum toxin A injection for facial wrinkles: A histological and immunohistochemical evaluation. *J Cosmet Dermatol* 2015;14:140–144.
25. Li Y, Hsieh ST, Chien HF, Zhang X, McArthur JC, Griffin JW. Sensory and motor denervation influence epidermal thickness in rat foot glabrous skin. *Exp Neurol* 1997;147:452–462.
26. American Society of Plastic Surgeons. 2017 Plastic Surgery Statistics Report. <https://www.plasticsurgery.org/documents/News/Statistics/2017/plastic-surgery-statistics-report-2017.pdf>. Accessed 16 August 2019.

Index



Page references followed by “f” denote figures, “t” denote tables, and “b” denote boxes.

A

Acetylcholine, 4
Acne/acne scars
 atrophic, 110t–111t, 112, 184f, 186
 description of, 57
 laser treatment for, 185–186, 185f
 microneedling for, 110t–111t, 112
 pathogenesis of, 185
 polydioxanone threads for, 224f
Actinic elastosis, 144
Actinic keratosis, 116t–117t, 117
Acupuncture, 3
Adenosine triphosphate, 181
Adipose tissue grafting, 221–222
Adipose-derived stem cells, 222
AFG. See Autologous fat grafting.
Aging skin. See Skin aging.
Alaria exculenta extract, 205, 205b
Alb-PRF
 clinical applications of, 221, 221f, 228, 228f
 description of, 127f, 218
 in vivo studies of, 220, 220f
 liquid platelet-rich fibrin versus, 220f
 in periorbital region, 145
 protocol for producing, 218–219, 219f
 in temple, 134
Alopecia
 androgenetic, 22, 92, 112–113, 114t–115t
 differential diagnosis of, 64
 microneedling for, 112–113, 114t–115t
 scarring, 75b
 traction, 75b
Alopecia areata, 75b, 76, 113, 114t–115t
Alopecia totalis/universalis, 75b
Alpha granules, 83
Anagen effluvium, 75b
Anagen phase, of hair growth, 21, 22f
Androgen(s), 22
Androgenetic alopecia, 22, 92, 112–113, 114t–115t
Angiogenesis
 platelet concentrates for, 25, 95
 platelet-rich plasma for, 95
Angular artery, 131, 143
Anticoagulants, 1, 80
Antioxidants, 204
Apex nasi, 11f
Archiving of photographs, 41
Arctic Čaga extract, 202–203, 203f, 208
Arnica, 207–208
Arrector pili muscle, 20, 21

ASCs. See Adipose-derived stem cells.
ATP38, 183
Atrophic acne scars, 110t–111t, 112, 184f, 186
Autologous fat grafting
 facial esthetics uses of, 221–222, 222f
 for marionette lines, 157

B

Basic fibroblast growth factor, 181
Benzocaine, lidocaine, and tetracaine creams, 167
Beta-glucans/beta-glucan M, 204, 205
bFGF. See Basic fibroblast growth factor.
Bioelectric stimulation, for hair loss, 226, 226f
BIO-PRF centrifuge, 89f
BIO-PRF lift, 128–130
Blepharochalasis, 10f
Blood assessment, 54
Blood centrifugation, 80, 80f
Bluish skin, 57
Bone(s)
 aging effects on, 23
 of face, 12f
Botox
 description of, 1
 forehead applications of, 137–138
 muscle denervation and relaxation caused by, 4
 recommendations for, 4
 safety of, 5, 5b
 secondary effects of, 4
Brow lifting, high-intensity focused ultrasound for, 226
Brow positioning, 45f
Brownish skin, 57
Bulla, 57, 57f
Burn scars
 illustration of, 101f
 microneedling for, 110t–111t
4-Butylresorcinol, 116

C

Café-au-lait macules, 186–187
CAL. See Cell-assisted lipotransfer.
CALMs. See Café-au-lait macules.
Camera, 30–32, 30f–32f
Cannula technique
 in jawline, 161
 in marionette lines, 157, 157f
 in nasolabial folds, 151

Cannulas, 125, 125f, 126t
Canon Veos-SLR/Hair photography package, 70, 70f
Carbon dioxide lasers
 description of, 176, 184
 skin resurfacing uses of, 188
Catagen phase, of hair growth, 21, 22f
Cell-assisted lipotransfer, 222
Cellular antioxidative assay, 203
Centrifugation
 description of, 80, 80f
 fibrin clot formation from, 82
 horizontal, 86, 87f, 89f
 illustration of, 104f
 leukocytes from, 84f
 low-speed centrifugation concept, 79, 84–85
Centrifuge, horizontal, 87f, 89f, 92, 104f, 127
Cheek
 aging of, 146
 anatomy of, 146, 146f
 high-risk zones of, 147, 147f
 platelet-rich fibrin injections in, 146–149, 146f–149f
 treatment of, 147f–148f, 148–149
Chin
 aging of, 158, 158f
 anatomy of, 158, 158f
 high-risk zones in, 159, 159f
 intravascular injection in, 159
 platelet-rich fibrin injections in, 158–161, 158f–161f
 treatment of, 159–160
 vertical suprapreriosteal depot technique in, 160
Chromophores, 181, 189
Chronological aging, 100
Club hairs, 21
CO₂ lasers. See Carbon dioxide lasers.
Cold packs, 124
Collagen-1, 88, 89f, 108f
Collagen induction therapy. See Microneedling.
Collagen synthesis, 2
Columella, 11f
Consultation
 clarifying of patient expectations at, 52–53
 considerations for, 52
 hair loss treatment. See Hair loss, consultation for.
 informed consent for, 61

initial, 44t, 44–53, 45f–52f
 lifestyle factors, 54
 manual assessment, 58, 58f–59f
 medical examination, 54
 Merz full esthetic scale, 44, 44t, 45f–52f
 one-on-one, 52
 overview of, 43
 psychologic assessment, 54
 summary of, 61
 treatment planning from, 60
 visual examination, 54, 55f, 56t, 57f
 Corrugator supercilii muscle, 138
 Cross-sectional trichometry, 67–68, 68f–69f
 Crow's feet. *See* Lateral canthal lines.
 Cuvet skin care products
 application of, 208–213, 209f–213f, 209t–213t
 Exfoliating Foaming Cleanser, 208, 209f, 209t
 Instant Vitamin Ampoules, 203, 203f, 210, 210f, 210t
 Protective Day Cream, 206, 206f, 212, 212f, 212t
 Renewal Night Cream, 212–213, 213f, 213t
 Stimulating Serum, 210, 211f, 211t
 24-hour protocol for, 209f
 Cytochrome C oxidase, 180
 Cytokines, 83–84

D

Deep cannula technique, 145
 Deep medial cheek fat compartment, 142
 Dehydration, of skin, 2
 Delta aminolevulinic acid photodynamic therapy, 117
 Deoxyhemoglobin, 182
 Depressor anguli oris, 156
 Dermal fillers
 blindness associated with, 5
 complications of, 131
 description of, 1, 4f
 lip augmentation uses of, 4f
 platelet-rich fibrin and, 130, 218
 safety of, 5, 5b
 Dermal papilla, 21
 Dermapen, 92, 93f, 99, 100f, 101, 119
 Dermis, 19, 177, 177f
 Digital compact cameras, 30f
 Digital reflex cameras, 30f
 Dihydrohelenalin, 207
 DMC. *See* Deep medial cheek fat compartment.
 Documentation
 consultation, 58, 59f
 esthetic treatments, 59f
 photography, 28, 35–41

“Dr. Acula’s Facial,” 192, 193f
 Dracula technique, 192, 193f
 Drooping mouth corners, 156f
 Dry skin, 57
 Dye laser, 180

E

Efflorescence, 57, 57f
 Electromagnetic radiation, 179
 Electromagnetic spectrum, 179
 Embolism, angular artery, 143
 Epicranium muscle, 136
 Epidermis
 anatomy of, 19, 21, 177, 177f
 lesions of, 187
 rejuvenation of, 204–206, 205f
 Epithelialization, 178
 e-PRF, 92–93, 129t, 220
 Ergonomics, 124, 125f
 Er:YAG lasers, 176, 182, 188, 192
 Esthetic medicine. *See also* Facial esthetics.
 procedures in, 5b, 5–6
 specialties included in, 5
 unesthetic features treated with, 4b
 Excimer laser, 180
 Excoriation, 57, 57f
 Exfoliating Foaming Cleanser, 208, 209f, 209t
 Extrinsic aging, of skin, 100
 Eyebrow ptosis, 10f

F

Face
 aging of, 10f, 10–11, 23, 24f, 118
 anatomy of, 10–19, 131–132, 10f–19f
 arteries of, 15–16, 15f–16f
 blood supply to, 15–16, 15f–16f
 bones of, 12f
 bony prominence assessment, 58f
 deep fat distribution in, 14, 14f, 23
 demarcations of, 2
 fat distribution in, 14, 14f
 features of, 53
 functions of, 10
 innervation of, 17–18, 17f–18f
 measurement landmarks for, 11f
 muscles of, 13, 13f
 regions of, 130b
 skeleton of, 12f
 subcutaneous fat of, 14, 14f, 24f
 superficial fat distribution in, 14, 14f
 vascular “danger zones” of, 131–132, 131f–132f
 veins of, 15–16, 15f–16f
 Facial artery, 150
 Facial esthetics
 adipose tissue grafting, 221–222
 autologous fat grafting, 221–222, 222f

consumer demand for, 6
 growth of, 1
 inflammation control after, 203
 lasers for, 176
 Merz scale, 44, 44t, 45f–52f
 microfocused ultrasound for, 225
 platelet-rich fibrin in, 92–93, 93f–94f, 124

Facial expression
 lines caused by, 60t
 muscles of, 150f
 Facial nerve, 18
 Facial rejuvenation
 biomaterials for, 3–5
 microneedling for, 108, 108f–109f
 traditional methods for, 3
 Facial scars, 110t–111t. *See also* Scar(s).
 Female pattern hair loss, 75b
 Fibrin clot, 82
 Fibrin matrix, 82, 85
 Fibrinogen, 82
 Fibroblasts, 87f, 178f
 Fibronectin, 88
 Fibroplasia, 178
 Fibrosis agents, 83–84
 Fitzpatrick classification, 54, 55f, 56t
 Fixed-angle centrifuge, 87f
 Flash light, 33, 35f
 Flavonoids, 207
 Forehead
 aging of, 136, 137f
 anatomy of, 136, 136f
 botulinum toxin type A treatment of, 137
 high-risk zones of, 137
 liquid platelet-rich fibrin and hyaluronic acid injection in, 223f
 Merz esthetic scale for, 45f
 platelet-rich fibrin injections in, 136–138, 136f–138f
 retrograde linear threading injections in, 138, 138f
 Forehead lines, 10f, 136, 137f–138f
 Fotona Lightwalker, 190, 191f
 Fractional ablation, 188–189
 Fractional photothermolysis, 187–188
 Frontalis muscle, 137

G

Gaseous lasers, 180
 Glabella
 aging of, 138, 139f
 anatomy of, 11f, 138, 139f
 frown lines in, 139f
 as high-risk area, 131
 high-risk zones of, 140, 140f
 platelet-rich fibrin injections in, 138–141, 139f–141f
 serial point injections in, 140
 Glabellar lines, 10f, 48f, 139f

Glogau classification, of photoaging, 54, 56t
 “Golf ball chin,” 159
 Greasy skin, 57
 Greater occipital nerve anesthesia, 168
 Growth factors. *See also specific growth factor.*
 microneedling release of, 107
 platelet release of, 118
 in platelet-rich fibrin, 80, 83–84

H

Hair
 function of, 20–22
 growth cycle of, 21–22, 22f
 layers of, 21
 loss of, 22
 structure of, 20–22
 Hair follicle, 20, 20f
 Hair loss
 bioelectric stimulation for, 226, 226f
 case studies of, 170–172, 170f–173f
 consultation for
 cross-sectional trichometry, 67–68, 68f–69f
 documentation, 70–74, 76, 70f–74f
 examination, 64, 67f–74f, 67–75
 forms, 65f–66f, 73f–74f
 hair pull test, 67, 67f
 hair tug test, 67, 67f
 history-taking, 64, 65f–66f
 informed consent, 71, 76
 laboratory investigations, 75
 photographic documentation, 70–74, 76, 70f–74f
 privacy issues, 64
 scalp examination, 67, 67f
 treatment planning after, 76
 trichoscopy, 70, 70f
 differential diagnosis of, 75, 75b
 female pattern, 75b
 goals for, 166
 indications for, 76
 Ludwig scaling system, 72, 72f
 male pattern, 75b
 nappage technique for, 169, 169f
 Norwood scaling system, 72, 72f
 point-by-point injection technique, 169, 169f
 prevalence of, 63–64, 165
 scalp
 anesthesia of, 166–168, 167f–169f
 anterior, 168, 168f
 biopsy of, 72
 examination of, 67, 67f, 69f
 innervation of, 167, 167f
 photographic documentation of, 71, 71f
 posterior, 168, 168f
 regional block of, 167

 topical anesthesia of, 166–167
 summary of, 172
 techniques for, 169–170, 169f–170f
 type of, 75b
 Hair Mass Index, 68, 68f
 Hair pull test, 67, 67f
 Hair removal, using lasers, 189–190
 Hair tug test, 67, 67f
 Hair zones, 21
 HairCheck, 69f
 Hands, 51f
 Healing, wound. *See* Wound healing.
 Helenalin, 207
 Hemangiomas, 186
 Hereditary hemorrhagic telangiectasia, 186
 HIFU. *See* High-intensity focused ultrasound.
 High-intensity focused ultrasound, 225–226
 High-intensity light, 180
 History taking
 for facial esthetics consultation, 54
 for hair loss consultation, 64, 65f–66f
 HMI. *See* Hair Mass Index.
 Horizontal centrifugation, 86
 Horizontal centrifuge, 87f, 89f, 92, 104f, 127
 Hyaluronic acid
 description of, 1
 liquid platelet-rich fibrin with, 222, 223f
 platelet-rich fibrin with, 151, 222, 223f
 skin dehydration prevention uses of, 2
 Hypertrophic scars
 laser treatment for, 184
 microneedling for, 110t–111t
 Hypodermis, 19, 177, 177f

I

Immune cells, 202
 Indirect flash light, 33, 35f
 Inferior alveolar artery, 159
 Inflammation, 203
 Informed consent, 61, 71, 76
 Infraorbital artery, 143
 Infraorbital foramen, 143
 Infraorbital hollowness, 52f
 Injectable platelet-rich fibrin, 85. *See also* Platelet-rich fibrin injections.
 Intrinsic aging, of skin, 100

J

Jawline, 50f
 aging of, 158, 158f
 high-risk zones in, 158, 159f
 platelet-rich fibrin injections in, 158–161, 158f–161f
 sagging of, 158
 treatment of, 160–161

Jowl, 160, 161f
 Juvenessence AD, 205, 205b

K

Keloid scars
 laser treatment for, 184
 microneedling for, 112, 113f
 Keratinocytes, 107, 178, 187
 Krypton/Nd:YAG laser, 188

L

Langerhans cells, 19, 203
 Laser(s)
 acne scars treated with, 185–186, 185f
 biologic activity of, 176–183
 carbon dioxide, 176
 classification of, 180, 182–183, 184f
 in combination therapy, 228, 228f
 dye, 180
 epidermal lesions treated with, 187
 Er:YAG, 176, 182, 188, 192
 facial esthetics uses of, 176
 fat ablation uses of, 189
 gaseous, 180
 hair removal uses of, 189–190
 hemangiomas treated with, 186
 history of, 175–176
 illustration of, 179f
 indications for, 183–195, 184f–188f, 191f–195f
 krypton/Nd:YAG, 188
 lipolysis uses of, 189
 low-level laser therapy. *See* Low-level laser therapy.
 microneedling versus, 109
 Nd:YAG, 180, 182, 184, 187, 190
 nonablative, 188
 photobiostimulation uses of, 180
 phototherapy uses of, 180–181
 pigmented lesions treated with, 186f–187f, 186–188
 platelet-rich fibrin and, in facial esthetics, 190–192, 191f–195f
 pulsed dye, 184, 186, 190
 Q-switched, 187, 190
 scars treated with, 184–185, 184f–185f
 skin rejuvenation uses of, 188–189
 solid, 180
 sun exposure after treatment with, 190
 sunscreen use after, 187
 therapeutic effects of, 181–182
 tissue interactions, 180
 vascular lesions treated with, 186
 wound healing uses of, 176–178
 Laser light, 179–181

Latanoprost sodium, 116
 Lateral canthal lines, 10f, 46f, 142
 LED devices. *See* Light-emitting diode devices.
 Lens, 30–32, 30f–32f
 Lesser occipital nerve anesthesia, 168
 Leukocyte(s), 80, 83, 84f
 Leukocyte platelet-rich fibrin, 81, 82f
 Lidocaine, for regional scalp block, 167
 Lifestyle factors, 54
 Light-emitting diode devices
 description of, 176
 photobiostimulation uses of, 181–182
 skin rejuvenation uses of, 189
 Lighting, 33, 34f–35f
 Lingonberry stem cell extract, 204–205, 205f
 Lingostem, 204–205, 205f
 Lip(s)
 aging of, 152–153
 anatomy of, 152, 152f
 augmentation of, dermal fillers for, 4f, 94
 blood supply to, 152
 corner of, 154
 Er:YAG laser treatment of, 192f
 fullness of, 47f
 high-risk zones of, 153, 153f
 liquid platelet-rich fibrin and hyaluronic acid injection in, 223f
 perioral lines, 153–154, 153f
 platelet-rich fibrin injections in, 152–156, 152f–155f
 volumizing treatment of, 154–155, 155f
 wrinkles around, 49f
 Liplase, 191–192, 192f
 Lipolysis, 189
 Liquid platelet-rich fibrin
 Alb-PRF versus, 220f
 centrifugation protocols for, 86f
 clinical uses of, 86
 clotting of, 86
 collection of, 91f, 104f
 description of, 1
 development of, 85–86
 facial filler with, 93
 hair loss treated with, 170f
 horizontal centrifugation, 86
 hyaluronic acid with, 222, 223f
 illustration of, 127f
 low-level laser therapy with, 170f–171f, 192, 194f–195f
 mesotherapy by syringe injections using, 93, 94f
 microneedling with, 92–93, 93f, 106f, 195f
 protocols for, 92
 regenerative potential of, 87f, 87–88
 syringe injections of, 93, 94f
 topical application of, 93f

Living skin equivalents, 203
 LLLT. *See* Low-level laser therapy.
 Local anesthesia, 130
 Loupe glasses, 125
 Lower face, platelet-rich fibrin injections in, 152–161, 152f–161f
 Low-level laser therapy
 acne vulgaris treated with, 185–186
 devices, 183, 183f
 history of, 176
 limitations of, 181–182
 liquid platelet-rich fibrin with, 170f–171f, 192, 194f–195f
 photobiostimulation uses of, 181–182
 skin rejuvenation uses of, 189
 Low-speed centrifugation concept, 79, 84–85
 L-PRF. *See* Leukocyte platelet-rich fibrin.
 Ludwig scaling system, 72, 72f
 Luer-Lok connector, 218, 220f
 Luer-Lok syringes, 125

M

Macule, 57, 57f
 Male pattern hair loss, 75b
 MAL-PDT. *See* Methyl aminolevulinate photodynamic therapy.
 Mandibular nerve, 17
 Marionette lines
 aging of, 156, 156f
 anatomy of, 156, 156f
 combination therapy for, 228, 228f
 high-risk zones, 156
 illustration of, 10f, 46f
 platelet-rich fibrin injections in, 156–157, 156f–157f
 treatment of, 157, 157f
 Matrix metalloproteinases, 20
 Maxillary nerve, 17
 Medical examination, 54
 Megakaryocytes, 83
 Melanin, 182, 189
 Melanocytes, 19–21
 Melanosomes, 186
 Melasma, 114t–115t, 116
 Mental foramen, 159
 Mentalis muscle, 158
 Merz full esthetic scale, 44, 44t, 45f–52f, 58
 Mesenchymal stem cells, 221
 Mesenchyme, 177
 Mesotherapy, 128, 129t
 Methyl aminolevulinate photodynamic therapy, 117
 Microfocused ultrasound, 225
 Microneedling
 acne scars treated with, 110t–111t, 112
 actinic keratosis treated with, 116t–117t, 117
 advantages of, 107

alopecia treated with, 112–113, 114t–115t
 in combination therapy, 228, 228f
 complications of, 107
 contraindications for, 101–102
 definition of, 100, 118
 depth chart for, 105f
 Dermalpen for, 92, 93f, 99, 100f, 101, 119
 description of, 3, 99
 facial rejuvenation uses of, 108, 108f–109f
 growth factors released after, 107
 indications for, 101–102
 keloid scars treated with, 112, 113f
 lasers versus, 109
 liquid platelet-rich fibrin with, 92–93, 93f, 106f, 195f
 melasma treated with, 114t–115t, 116
 neovascularization, 99
 periorbital melanosis treated with, 114t–115t, 116
 pigmentary disorders treated with, 113–116, 114t–117t
 platelet-rich fibrin with
 in cheek, 148
 description of, 102, 103f–106f, 128–129, 129b
 in forehead, 138
 for hair loss, 171f
 in jawline, 161
 in lips, 155
 in temple, 135
 scars treated with, 109–112, 110t–112t
 science of, 107–117
 skin penetration with, 201
 stretch marks treated with, 118, 119f
 summary of, 118
 treatment goals after, 100f
 verruca treated with, 117
 vitiligo treated with, 114t–115t, 116
 Midface, platelet-rich fibrin injections in, 146–151, 146f–151f
 Minimally invasive procedures
 statistics regarding, 6f
 types of, 1
 Mirror, 124
 MMPs. *See* Matrix metalloproteinases.
 Monocytes, 118
 Muscles, of face, 13, 13f

N

Nappage technique, 169, 169f
 Nasolabial creases, 150
 Nasolabial folds
 aging of, 149–150
 anatomy of, 10f, 32f, 149, 150f
 combination therapy for, 228, 228f
 high-risk zones of, 150f, 150–151
 laser treatment of, 191f

- platelet-rich fibrin injections in, 149–151, 150f–151f
 Smoothlase application for, 191f
 Nasolabial lines, 48f
 Nd:YAG lasers, 180, 182, 184, 187, 190
 Neck
 elastosis of, 10f
 Merz esthetic scale for, 51f
 Neck lines, 10f
 Needles, for platelet-rich fibrin, 125, 125f–126f, 126t
 Neovascularization, 99
 Neutrophils, 118
 Nodule, 57, 57f
 Nonscarring alopecia, 166
 Norwood scaling system, 72, 72f
 Nose, 131
- O**
- Omega-3, 206–207, 207f
 Omegatri, 206–207, 207f
 Ophthalmic artery, 140
 Ophthalmic nerve, 17
 Oral commissures, 49f
 Orbicularis oculi muscle, 142, 152
 Oxyhemoglobin, 182
- P**
- Palpebromalar groove, 143, 145f
 Panthenol, 204
 “Papule,” 129f, 129t
 Paralyzers, 1
 Patient expectations, 52–53
 PDGF. *See* Platelet-derived growth factor.
 PDL. *See* Pulsed dye lasers.
 PDO threads. *See* Polydioxanone threads.
 Peptides, 206, 206f
 Periocular lines, 10f
 Perioral lines, 153–154, 153f
 Perioral region, 152–156, 152f–155f
 Periorbital melanosis, 114t–115t, 116
 Periorbital region
 aging of, 142f, 142–143
 anatomy of, 142, 142f
 high-risk zones of, 143
 lateral canthal lines, 142–143, 144f
 palpebromalar groove, 143, 145f
 platelet-rich fibrin injections in, 141–145, 142f–145f
 tear troughs, 143–144, 144f
 upper eyelids, 142
 Peripheral blood, platelet-rich fibrin collection from, 88–91, 89f–91f
 Philtral columns, 154
 Photoablation, 180
 Photoaging, Glogau classification of, 54, 56t
 Photochemical effect, 180
 Photodisruption, 180
 Photodynamic therapy, 117, 180–181
 Photographs
 archiving of, 41
 in hair loss consultation, 70–74, 76, 70f–74f
 taking of, 35
 Photography
 background of, 29, 29f
 camera, 30–32, 30f–32f
 documentation series, 28, 35–41
 facial esthetics use of, 29
 functions of, 28
 general requirements for, 28–29
 lens, 30–32, 30f–32f
 lighting of, 33, 34f–35f
 marketing of, 41
 Phototherapy
 acne vulgaris treated with, 185
 description of, 180–181
 Photothermal effect, 180
 Photothermolysis, fractional, 187–188
 Phototrichogram, 67
 Pigmentary disorders. *See also specific disorder.*
 laser treatment for, 186f–187f, 186–188
 microneedling for, 113–116, 114t–117t
 Plasma ablation, 180
 Plasma heating, 218
 Plastic surgery, 226, 227f
 Platelet(s), 80, 83, 118
 Platelet concentrates
 advantages of, 1, 6
 angiogenesis promotion by, 25, 95
 centrifugal protocols for, 79
 function of, 2
 growth factors in, 80–81
 history of, 81–84
 medicinal uses of, 80–81
 platelet-rich plasma, 1
 Platelet-derived growth factor, 80, 83, 181
 Platelet-poor plasma, 218
 Platelet-rich fibrin
 advantages of, 3, 53, 94
 Alb-PRF. *See* Alb-PRF.
 angiogenesis promotion by, 25
 application of, 102, 103f–106f
 autogenous, 124
 cells in, 83
 clot formation, 80f, 91
 collection of, from peripheral blood, 88–91, 89f–91f
 in combination therapy, 228, 228f
 components of, 82f
 contraindications for, 124
 definition of, 3
 dermal fillers and, 130, 218
 description of, 1
 drawing up, 125, 126f, 130
 e-PRF, 92–93, 129t, 229
 facial esthetics use of, 92–93, 93f–94f, 124
 facial rejuvenation uses of, 92
 formation of, 80
 goals of, 5
 growth factors in, 83–84
 half-life of, 218
 heat-treated, 85
 history of, 81–84
 hyaluronic acid with, 222, 223f
 injectable, 85
 laser microchanneling with, 193f
 laser treatment and, 190–192, 191f–195f
 leukocytes in, 81, 82f, 83
 limitations of, 218
 liquid. *See* Liquid platelet-rich fibrin.
 low-level laser treatment and, 194f–195f
 matrix of, 82
 mechanism of action, 92
 medicinal uses of, 80–81
 plastic surgery with, 226, 227f
 platelet-rich plasma versus, 95
 platelets in, 83
 postoperative care, 102, 106f
 preparation of, 102, 103f–106f
 side effects of, 124
 technique with, 102, 103f–106f
 treatment protocol for, 44, 60
 types of, 127, 127f
 ulcers treated with, 81
 Platelet-rich fibrin injections
 accessories for, 124–125, 125f–126f
 BIO-PRF lift, 127–130, 128b–129b, 129f
 complications of, 131
 ergonomics for, 124, 125f
 global approach, 127–130, 128b, 129b, 129f
 hair loss treated with. *See* Hair loss.
 intraepidermic, 129t
 mesotherapy, 128, 129t
 needles for, 125, 125f–126f, 126t
 platelet-rich fibrin types for, 127, 127f
 pretreatment considerations for, 124–125, 125f–126f
 regional
 cheek, 146–149, 146f–149f
 chin, 158–161, 158f–161f
 description of, 127, 128b
 forehead, 136–138, 136f–138f
 glabella, 138–141, 139f–141f
 jawline, 158–161, 158f–161f
 lateral canthal lines, 142–143, 144f
 lips, 152–156, 152f–155f

- lower face, 152–161, 152f–161f
 marionette lines, 156–157, 156f–157f
 midface, 146–151, 146f–151f
 nasolabial folds, 149–151, 150f–151f
 perioral region, 152–156, 152f–155f
 periorbital region, 141–145, 142f–145f
 tear troughs, 143–144, 144f
 temple, 132–135, 133f–135f
 upper face, 132–145, 133f–145f
 vascular “danger zones” of face, 131–132, 131f–132f
 superficial intradermal “papule,” 129f, 129t
 tips for, 127
 topical anesthesia for, 125
- Platelet-rich fibrin stand, 125, 126f
- Platelet-rich plasma
 advantages of, 3
 autogenous, 80
 composition of, 81
 description of, 1
 history of, 81–84
 limitations of, 81
 platelet-rich fibrin versus, 95
 regenerative potential of, 87f, 87–88
- PLLA. See Poly-L-lactic acid.
- PMMA. See Polymethyl methacrylate.
- Point-by-point injection technique, for hair loss, 169, 169f
- Polydioxanone threads, 1, 222–223, 224f
- Poly-L-lactic acid, 222–223, 225
- Polymethyl methacrylate, 225
- Posttreatment skin care. See Skin care products.
- PPP. See Platelet-poor plasma.
- PRF. See Platelet-rich fibrin.
- PRFEDU facial esthetic photographic documentation series, 36, 39f–40f, 41
- Procerus muscle, 138
- Propionibacterium acnes*, 185
- Protective Day Cream, 206, 206f, 212, 212f, 212t
- PRP. See Platelet-rich plasma.
- Psychologic assessment, 54
- Pulsed dye lasers, 184, 186, 190
- Punch biopsy, of scalp, 72
- Pustule, 57, 57f
- Q**
- Q-switched lasers, 187, 190
- R**
- Reactive oxygen species, 20, 203f, 204, 208
- Recombinant human platelet-derived growth factor-BB, 83
- Red lip, 154, 155f
- Relative centrifugal force, 84
- Rem, 179
- Renewal Night Cream, 212–213, 213f, 213t
- Retrograde linear threading injections
 in forehead, 138, 138f
 in perioral region, 153
- Retro-orbicularis oculi fat pad, 142
- rhPDGF-BB. See Recombinant human platelet-derived growth factor-BB.
- ROOF. See Retro-orbicularis oculi fat pad.
- ROS. See Reactive oxygen species.
- S**
- Scalp
 anesthesia of, 166–168, 167f–169f
 anterior, 168, 168f
 biopsy of, 72
 examination of, 67, 67f, 69f
 innervation of, 167, 167f
 photographic documentation of, 71, 71f
 posterior, 168, 168f
 regional block of, 167
 topical anesthesia of, 166–167
- Scar(s)
 acne. See Acne/acne scars.
 atrophic, 110t–111t, 112, 184f
 burn
 illustration of, 101f
 microneedling for, 110t–111t
 formation of, 184
 hypertrophic, 184
 keloid
 laser treatment for, 184
 microneedling for, 112, 113f
 laser treatment for, 184–185, 184f–185f
 microneedling for, 109–112, 110t–112t
- Scarring alopecia, 75b
- Sebaceous glands, 20–21
- Selective photodermolysis, 176
- Serial point injections, 140
- Sharps container, 125
- Shedding, 64
- Skin
 aging of. See Skin aging.
 anatomy of, 176–177
 bluish, 57
 brownish, 57
 color of, 56f, 57
 dehydration of, 2
 dry, 57
 efflorescence of, 57, 57f
 ethnic differences in, 19–20
 external factors that affect, 57
 Fitzpatrick classification of, 54, 55f, 56t
 functions of, 19
 greasy, 57
 hydration of, 58f
 laser resurfacing of, 188–189
 layers of, 19
 light penetration into, 181f
 manual assessment of, 58, 58f–59f
 omega-3’s effects on, 207
 reddening of, 57
 rejuvenation of, using lasers, 188–189
 smoking effects on, 118
 structure of, 19
 texture of, 57
 ultraviolet radiation exposure, 208
 wrinkles of, 58, 60t
 yellowish, 57
- Skin aging
 changes associated with, 2, 3b, 19–20
 characteristics of, 2f, 2–3, 19–20
 chronological, 100
 ethnic differences, 19–20
 extrinsic, 100
 factors associated with, 2, 20, 99
 healing or regeneration of, 1
 intrinsic, 100
 treatment options for, 2–3
- Skin care products
Alaria exculenta extract, 205, 205b
 antioxidants, 204
 Arctic Čaga extract, 202–203, 203f, 208
 arnica, 207–208
 beta-glucan M, 205
 Čuvget. See Čuvget skin care products.
 description of, 201
 lingonberry stem cell extract, 204–205, 205f
 omega-3, 206–207, 207f
 peptides, 206, 206f
 SYN-TC, 206, 206f
- Skin markers, 124
- Skin rejuvenation, 189, 202
- Skin snap test, 58, 58f
- SMAS. See Superficial musculoaponeurotic system.
- Smoker’s lines, 153
- Smoking, 118
- Smoothlase, 190–191, 191f–192f
- Snap test, 58, 58f
- Sodium ascorbyl phosphate, 204
- Sodium carboxymethyl beta-glucan, 205
- Soft tissue nasion, 11f
- Solid lasers, 180
- SOOF. See Suborbicularis oculi fat pad.
- Stimulating Serum, 210, 211f, 211t
- Stratum corneum, 19
- Stretch marks, 118, 119f
- Subcutaneous tissue, 19, 60t
- Subnasale, 11f

Suborbicularis oculi fat pad, 142, 146
 Subsurfacing, 188
 Sun exposure, 2
 Sunscreen, 187
 Superficial intradermal “papule,” 129t
 Superficial musculoaponeurotic system, 14, 147, 158, 225
 Superficial temporal artery, 132, 134f
 Supraorbital artery, 132
 Supraperiosteal injections, 147f, 160f
 Supratrochlear artery, 137
 SYN-TC, 206, 206f

T

Tear troughs, 143–144, 144f
 Telangiectasias, 186
 Telogen effluvium, 75b
 Telogen phase, of hair growth, 21, 22f
 Temple
 aging of, 132, 133f
 anatomy of, 132, 133f
 high-risk zones in, 134f
 hollows formation in, 133f, 134–135
 vertical supraperiosteal depot technique in, 134, 135f
 Temporal fossa, 132
 Temporalis muscle, 132
 Terminal hairs, 20
 Testosterone, 22
 TGF- β 1. See Transforming growth factor- β 1.
 TGF- β 3. See Transforming growth factor- β 3.

Tinea capitis, 75b
 Tissue regeneration, 83
 Tocopherol acetate, 204
 Topical anesthesia, 125, 166–167
 Traction alopecia, 75b
 Transforming growth factor- β 1, 83–84, 85f, 181
 Transforming growth factor- β 3, 107
 Traumeel-S, 207
 Treatment planning, 60, 76
 Trichion, 11f
 Trichometry, cross-sectional, 67–68, 68f–69f
 Trichoscopy, 70, 70f
 Trichotillomania, 75b
 Trigeminal nerve, 17, 167

U

Ulcer, 57, 57f, 81
 Ultrasound
 high-intensity focused, 225–226
 microfocused, 225
 Ultraviolet light, 180, 182, 187
 Ultraviolet radiation, 20, 100, 208
 Upper eyelid hollows, 142

V

Vascular endothelial growth factor, 80, 84, 226
 Vascular lesions, 186
 VEGF. See Vascular endothelial growth factor.
 Vein light, 125

Vellus hairs, 20
 Verruca, 117
 Vertical supraperiosteal depot technique
 in cheek, 148
 in chin, 160
 in temple, 134, 135f
 Videodermoscopy, 70
 Visual examination, 54, 55f, 56t, 57f
 Vitamin B5, 204
 Vitamin C, 204
 Vitamin E, 204
 Vitiligo, 114t–115t, 116

W

Wheal, 57, 57f
 White lip, 154, 155f
 Wide-angled lens, 32
 Wound contraction, 178
 Wound healing
 description of, 80
 lasers for, 176–178
 leukocytes’ role in, 83
 phases of, 118, 177–178, 178f
 Wrinkles, 49f, 58, 60t

Y

Yellowish skin, 57

Z

Zygomatic bone, 146
 Zygomaticofacial artery, 147
 Zygomaticus muscle, 146, 146f