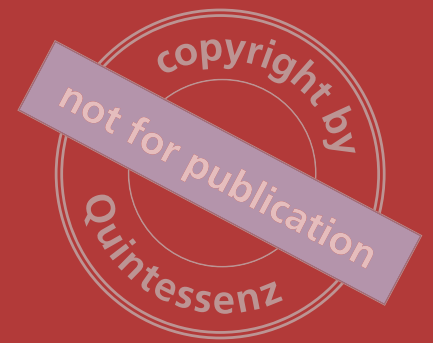

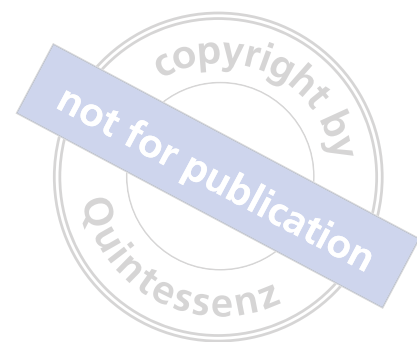Francis Louise
Oana Dragan

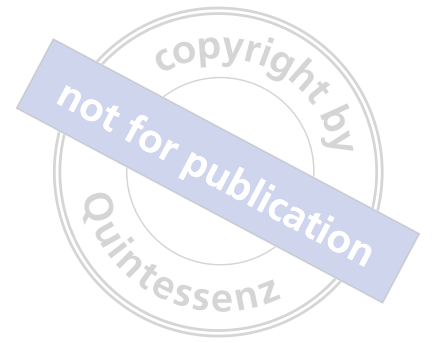

Essentials of Maxillary **Sinus Augmentation**

Francis Louise, Oana Dragan

Essentials of Maxillary Sinus Augmentation





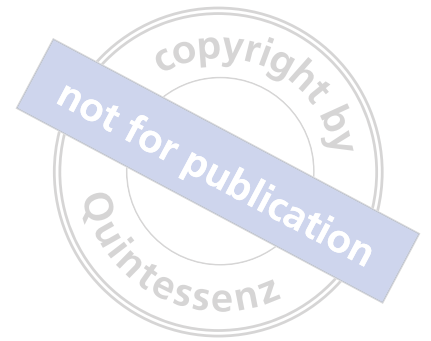Francis Louise, Oana Dragan

Essentials of Maxillary Sinus Augmentation

 **QUINTESSENCE PUBLISHING**

Berlin, Barcelona, Chicago, Istanbul, London, Milan, Moscow, New Delhi, Paris, Prague,
São Paulo, Seoul, Singapore, Tokyo, Warsaw

Cover from Piet Mondrian, 1921, Composition en rouge, jaune, bleu et noir.



A CIP record for this book is available from the British Library.

ISBN: 978-1-78698-018-2



Quintessence Publishing Co. Ltd,
Grafton Road, New Malden,
Surrey KT3 3AB,
United Kingdom
www.quintpub.co.uk

Copyright © 2018

Quintessence Publishing Co. Ltd

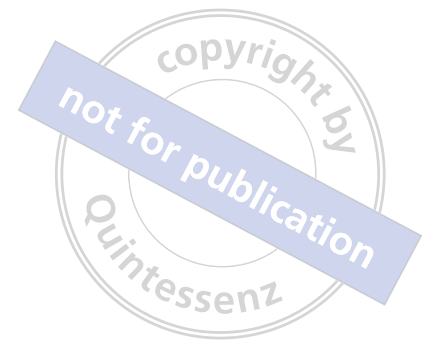All rights reserved. This book or any part thereof may not be reproduced, stored in a retrieval system, or transmitted in any form or by any means, electronic, mechanical, photocopying, or otherwise, without prior written permission of the publisher.

Editing: Elizabeth Ducker, Quintessence Publishing Co. Ltd, London, UK

Layout and Production: Andreas Merkert, Quintessenz Verlags-GmbH, Berlin, Germany

Reproduction: Quintessenz Verlags-GmbH, Berlin, Germany

Printed and bound in Germany by Bosch-Druck GmbH, Landshut/Ergolding



Foreword

It is my pleasure to write the foreword to this book by Professor Francis Louise and Dr Oana Dragan.

Dentistry has changed dramatically in recent decades. New biologic materials and technologies have enabled implementation of novel techniques and concepts in order to provide better treatment for our patients. However, the ever-increasing plethora of scientific and clinical information, in every aspect of the profession, is difficult for the clinician to follow. This is true for maxillary sinus elevation to accommodate implants in the posterior maxillary edentulous ridge.

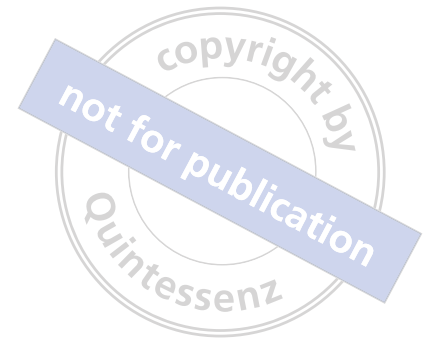Only two decades ago, extraoral autogenous donor sites had to be harvested to transfer bone to the sinus. Such treatments required not only additional surgery (at the donor site, such as the iliac crest or calvaria), but also caused patients considerable discomfort and mobility. The developments in this treatment modality, based on clinical evidence as well as on scientific studies, led to the present multiple techniques, all much less invasive and less time-consuming, with their obvious benefits for patients.

In this practical, methodical, and up-to-date book, Professor Francis Louise and Dr Oana Dragan clarify the current knowledge and scientific basis of this specific modern dental treatment, augmentation of the maxillary sinus for implant placement. In a stage-by-stage, didactic, and clear manner, they have been able to simplify and put together science-based insights and their clinical applications, unraveling for the reader the myths and revealing the secrets of the various options of this particular treatment modality. The logical and well-structured content of this book is perfect for any professional who seeks to be updated on the state-of-the-art concepts and techniques for maxillary sinus augmentation, and gain a clear and vast understanding of these treatments. This concept has improved the quality of life for millions of people throughout the world.

It is unusual that a dentistry book is spellbinding not only for the clinicians who implement this discipline, but also for those among us who read only for the pleasure of expanding their knowledge. I started this prologue with "It is my pleasure." I end it with the assurance that reading and learning from this excellent book will be a pleasure for any dentist.

Nitzan Bichacho, DMD

Professor, Faculty of Dental Medicine,
Hebrew University of Jerusalem, Jerusalem, Israel.



About the authors

Francis Louise

Professor and former Chairman at the Department of Periodontology, Head of Postgraduate Studies in Periodontics and Implantology, Faculty of Odontology, Aix-Marseille University, Marseille, France; and Private Practice, Marseille, France.

Professor Louise's latest research focuses on piezosurgery applications in implant dentistry.

Oana Dragan

Faculty of Dentistry, University of Medicine and Pharmacy, Cluj-Napoca, Romania; and Private Practice, Cluj-Napoca, Romania.

Dr Dragan's clinical interests and research focus on Endodontics (PhD), particularly diagnosis and treatment planning considerations for complex oral rehabilitation cases with implant-supported prosthetic restorations.

Contributors

Yves Macia

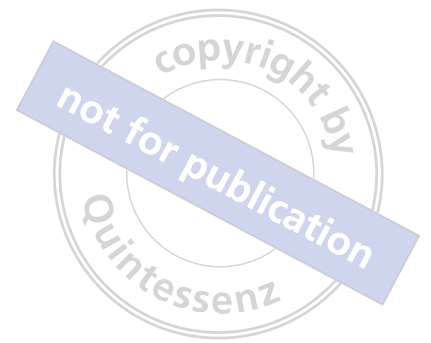Former Assistant in Oral Surgery, Faculty of Odontology, Aix-Marseille University, Marseille, France; and Private Practice, Marseille, France.

Fabien Vidot

Former Assistant in Periodontology, Faculty of Odontology, Aix-Marseille University, Marseille, France; and Private Practice, Marseille, France.

Xavier Zaehring

Former Assistant in Periodontology, Faculty of Odontology, Aix-Marseille University, Marseille, France; and Private Practice, Annecy, France.



Preface

Building learning power through vision and passion. Finding a new direction.

Writing a scientific book is always a challenge and a great responsibility. It is about sharing your knowledge and your own clinical experience linked to the scientific evidence, and has to be useful and easily accessible to the readers. You have to be accurate, concise, and complete.

In the 21st century, implants are considered to be the gold standard of care for replacing missing teeth in most clinical cases. The use of dental implants has been on the increase significantly in recent years because of the tremendous benefits of osseointegration and, in an equal measure, in response to patients' knowledge, need, and demand for implant therapy. This has led to rapid growth of the implant industry, fortunately accompanied by a marked development of the surgical techniques, implant surface treatments, coatings, and design, and prosthetic components. On the other hand, because an increasing number of patients and dentists rely on the Internet and other media sources for information regarding implant therapy, it is important to be aware of patients' unrealistic expectations, influenced by marketing strategies, and to advise clinicians to seek advanced training and reliable resources of information in order to achieve predictable, evidence-based, long-term success in implant surgery.

With all this in mind, we hope this book is a valuable and useful source of information for all those working in the field of dentistry (dental students, postgraduate residents, general dentists, and specialists), who want to know more about sinus augmentation procedures in restoring the posterior edentulous maxilla with dental implants. It is envisioned as a very accessible, complete, and clinical book that every dentist should have in their office, for clinical guidance in their treatment planning, or for performing a sinus augmentation procedure on their own.

The opportunity to consider an e-learning framework for this book proved to be a timely boost for our belief in sharing our knowledge and our sense of direction. We decided that choosing a multimedia publication would give us greater impetus than the traditional ways of learning to which we have been accustomed, and would bring us closer to our readers. It gave us the opportunity to reflect on the progress education and science have made so far, and to begin to focus on where they might go next.

May 2017

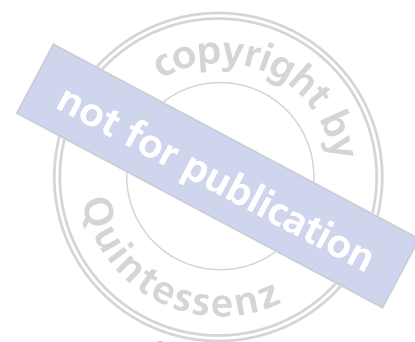A handwritten signature in blue ink, appearing to read "Francis Louise".

Francis Louise

A handwritten signature in blue ink, appearing to read "Oana Dragan".

Oana Dragan

Table of contents



Chapter 1

Sinus augmentation: General considerations **1**

The lateral approach	4
The crestal approach	8
Prerequisites for a predictable surgical outcome	8

Chapter 2

Anatomical landmarks: Preoperative evaluation **11**

Residual bone height and width	12
Sinus floor anatomy and bony septa	17
Available prosthetic space	20
Vascularization	21
Thickness of the antral wall	24
Sinus width	25
Sinus height and ostium location	26
Residual bone corticalization	27
Thickness of the sinus membrane	27

Chapter 3

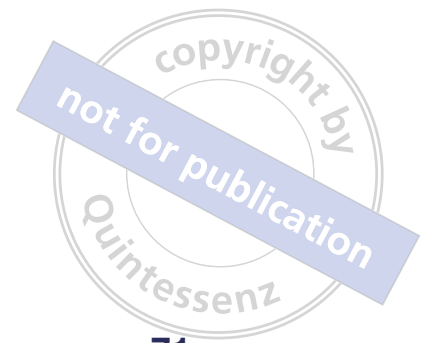Instruments and biomaterials **29**

Instruments for the mechanical technique	30
Instruments for the ultrasonic technique	34
Biomaterials used for sinus augmentation	41
Effect of biomaterials on healing of the grafted sinus	43

Chapter 4

The lateral approach technique **45**

Preoperative care and procedures	46
Surgical technique	46
Piezosurgery protocol	52
Variations of bony flap usage	61
Clinical cases	61



Chapter 5

The crestal approach technique

71

Preoperative care and procedures	72
Surgical techniques	72
Clinical cases	86
Bone grafting with the crestal approach	94

Chapter 6

Preoperative risk assessment and postoperative care

95

Preoperative risk assessment	96
Postoperative care and patient management	96
Sinus augmentation complications	96
Intraoperative complications	97
Postoperative complications	103

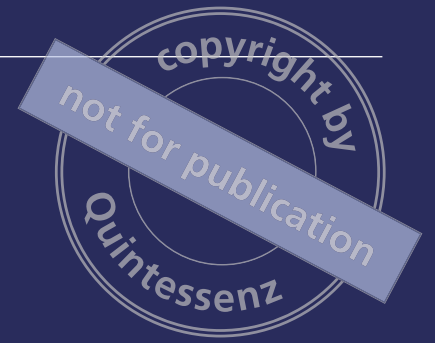References

110

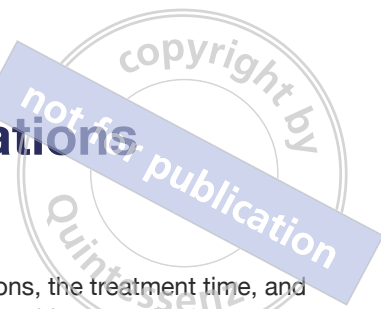Index

115

Sinus augmentation: General considerations



Sinus augmentation: General considerations



Sinus augmentation should be an integral part of the treatment of an atrophied posterior maxilla with dental implants. Sinus elevation is a surgical technique that, owing to the latest developments, can be routinely performed with success. It allows the safe placement of implants in maxillary edentulous posterior areas with insufficient bone volume caused by pneumatization of the maxillary sinus and crestal bone resorption.

When considering other possible choices of treatment in atrophied posterior sites of the maxilla (ie, short implants without sinus augmentation), the survival rate of implants should be taken into account. If the survival rate of implants placed with sinus augmentation is compared to those without (ie, using short implants), a higher rate is found for implants placed without sinus augmentation (86% for implants with sinus floor augmentation versus 96% for those placed into pristine bone), according to Barone et al (2011).

These results show that implants placed into pristine bone seem less subject to complications, possibly because the density of the bone grafted into the sinus may be lower. However, short implants, in the same way as regular-length implants, have a marginal peri-implant bone loss immediately after loading and 1 year later. (Monje et al, 2014) Moreover, non-splinted posterior short implants have a somewhat lower success rate than splinted short implants, and the failure rate in non-splinted short implants appeared to be greater in males and in implants less than 10 mm in length (Mendoncxa et al, 2014). On the other hand, if, after extraction, the bone socket of the maxillary molars is preserved by means of graft materials (advanced extraction therapy [AET]), the residual bone crest will be higher and sinus floor elevation can often be avoided (Figs 1-1 to 1-7) (Rasperini et al, 2010).

Since the first procedures described by Tatum (1986) on how to perform the augmentation of the sinus floor, many improvements have been made (such as radiographs and CT scans, manual and ultrasonic instruments, biomaterials placed into the sinus, and lateral or crestal approach techniques), leading to a high success rate when using the various sinus floor elevation procedures.

There are currently two treatment options when performing sinus augmentation to restore an edentulous posterior maxillary site: simultaneous or delayed implant placement. The simultaneous procedure reduces the

number of surgical interventions, the treatment time, and the financial cost. To perform this procedure successfully, sufficient residual bone height (RBH) is required, the usual recommendation being at least 5 mm; although this value was first suggested in 1989 (Kent and Block), it is still valid, notwithstanding the density of the existing bone.

The two-stage, delayed implant procedure gives the clinician the advantage of drilling and placing the implant while controlling the stability of the grafted site.

Using short implants (< 7 mm) instead of a sinus augmentation procedure could also be a solution. A recent systematic review (Esposito et al, 2014) showed that it is still unclear whether sinus procedures for residual ridges between 4 and 9 mm are more or less successful than placing short implants (5 to 8 mm) without any augmentation of the RBH. Based on the present authors' experience, short implants must be used in cases in which current sinus elevation techniques could not be successfully performed because of particular sinus anatomy or systemic contraindications.

All these observations have to be considered before including sinus augmentation routinely in treatment planning. The two possible approaches to perform a sinus elevation are outlined below.

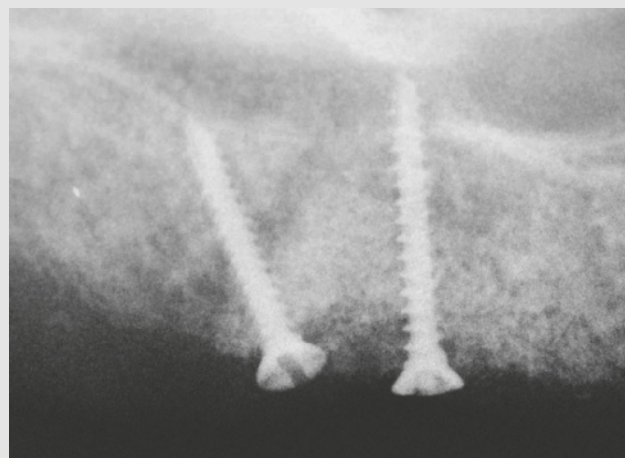


Fig 1-5 Intraoral radiographic control at 5 months.

copyright by
not for publication
Quintessenz

Socket preservation.

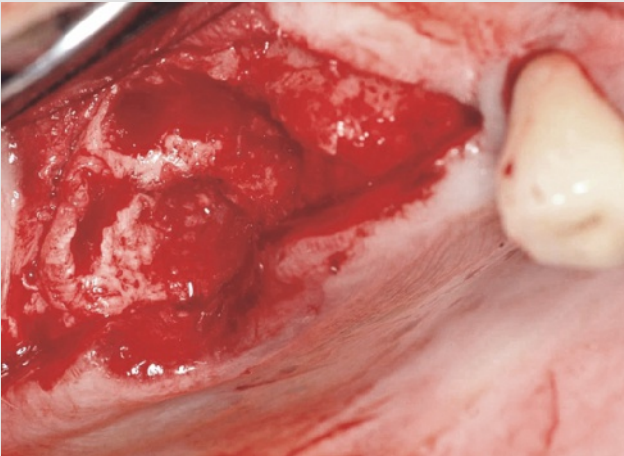


Fig 1-1 The extraction site immediately after completion of extraction.

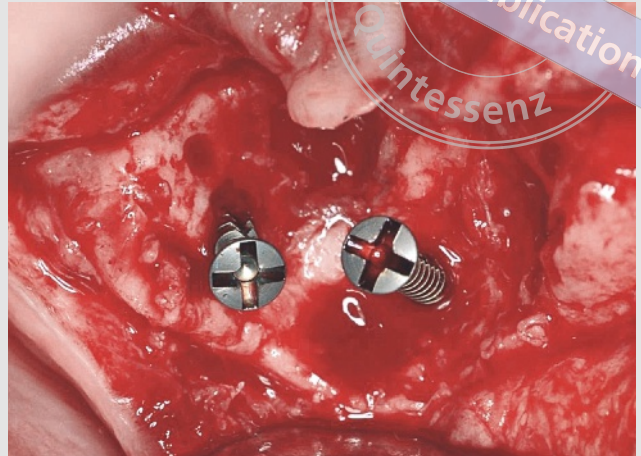


Fig 1-2 Tekka screws created a stable, retentive space for the bone graft material.

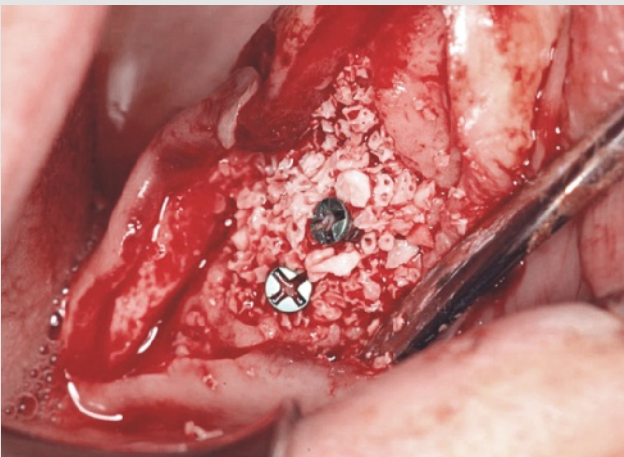

Fig 1-3 The socket was filled with BioOss (large particles; Geistlich).

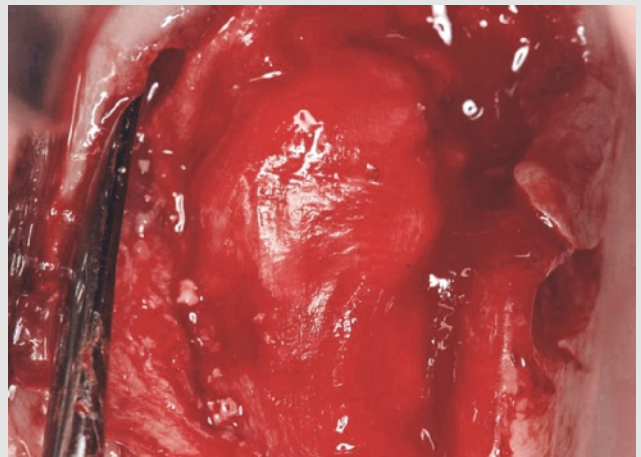


Fig 1-4 The site was covered with a BioGide (Geistlich) collagen membrane.

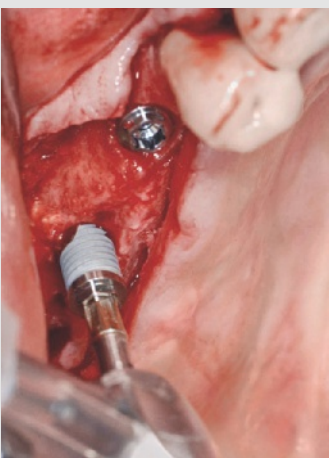


Fig 1-6 Placement of three implants (Brånemark MkIII; Nobel Biocare) in the grafted site at 9 months.

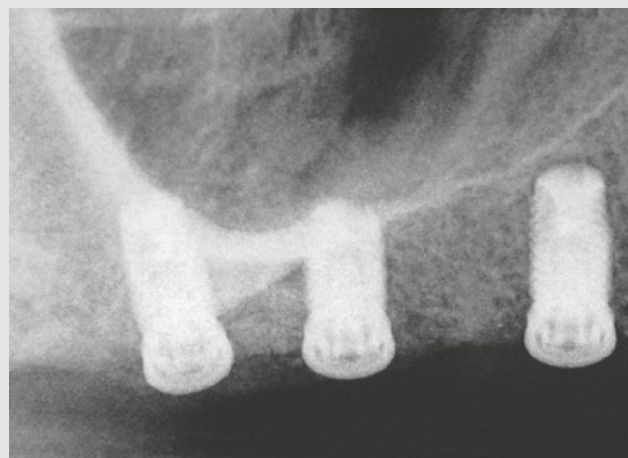

Fig 1-7 Intraoral radiographic control after osseous integration of the implants (13 months after sinus augmentation).

The lateral approach

The lateral approach consists of drilling an osseous window on the lateral wall of the sinus, elevating the sinus membrane, and filling the lower part of the sinus with osseous granules, and can be either:

- with immediate implant placement (Figs 1-8 to 1-16)
- with a delayed implant placement (Figs 1-17 to 1-24).

Lateral approach and immediate implant placement.

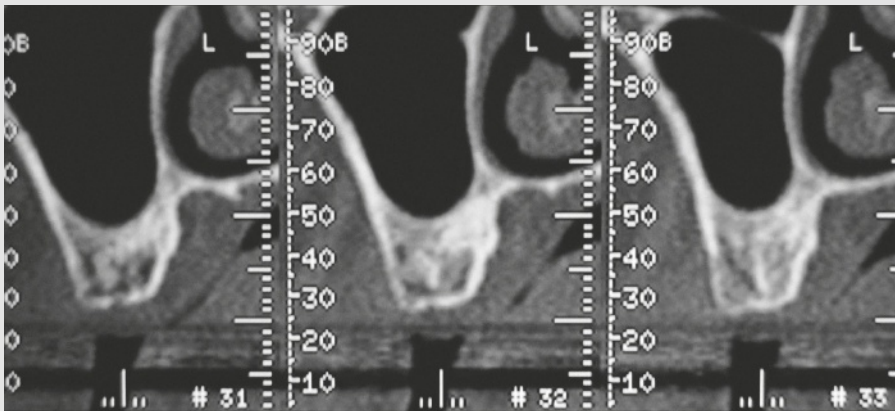


Fig 1-8 Right sinus view before treatment; CBCT coronal section.

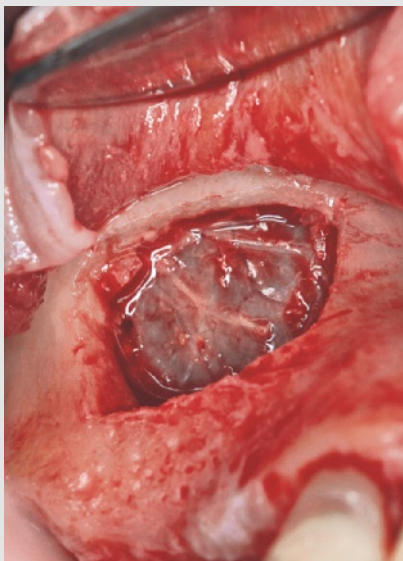


Fig 1-9a The integrity of the sinus membrane after the bony window removal.

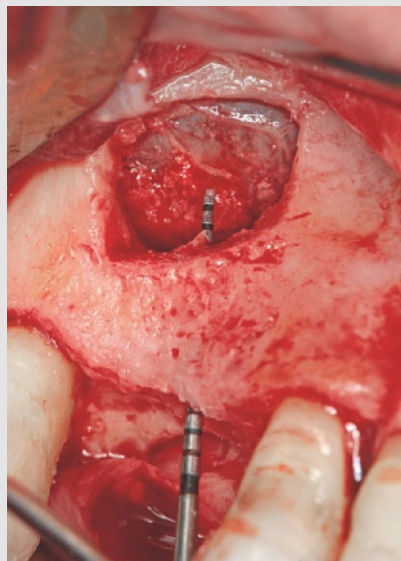


Fig 1-9b The available bone height was checked after membrane elevation.

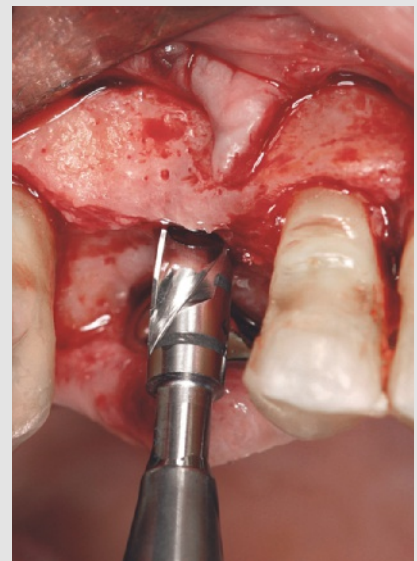


Fig 1-10 Implant site preparation.

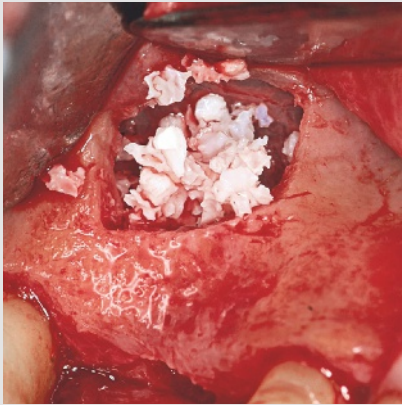


Fig 1-11 The sinus was filled with bio-material (BioOss, large particles; Geistlich).

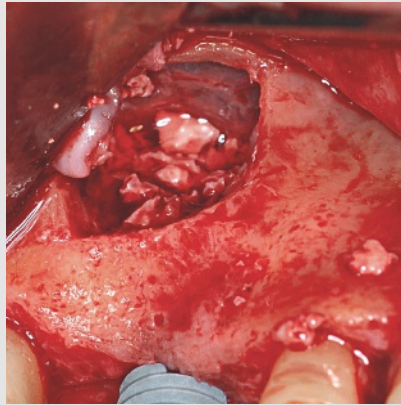


Fig 1-12 Implant placement (Brånemark MkIII, 11.5 × 5 mm; Nobel Biocare).

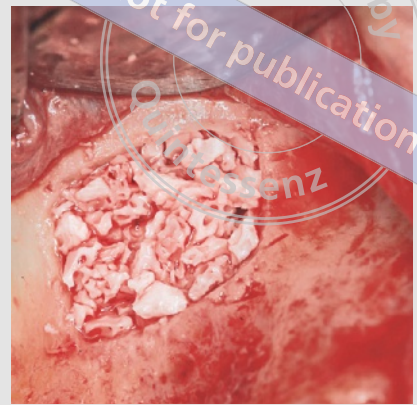

Fig 1-13 The remaining free spaces inside the sinus cavity were filled after locking the implant.

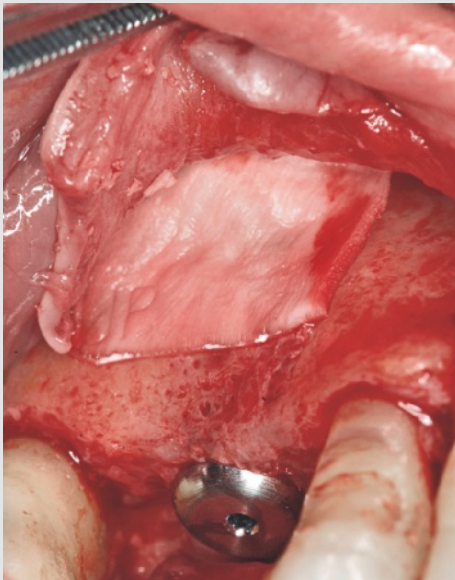


Fig 1-14 The site was covered with a collagen membrane (BioGide; Geistlich) for grafted site protection.

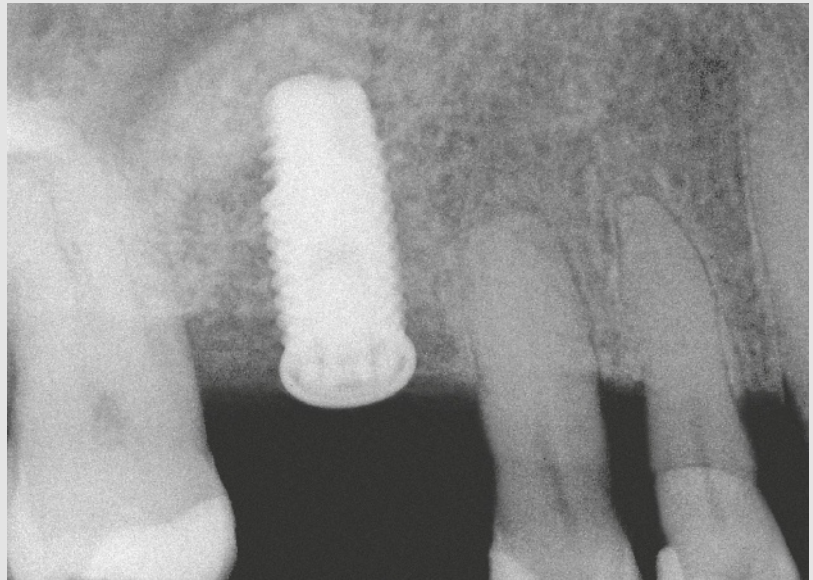


Fig 1-15 Immediate postoperative intraoral radiograph.

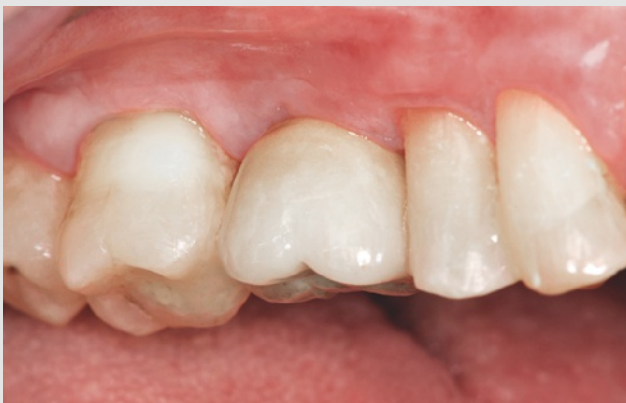

Fig 1-16 Final prosthetic work and the surrounding soft tissues (1 year postoperatively).

copyright by
not for publication
Quintessenz

Lateral approach and delayed implant placement.

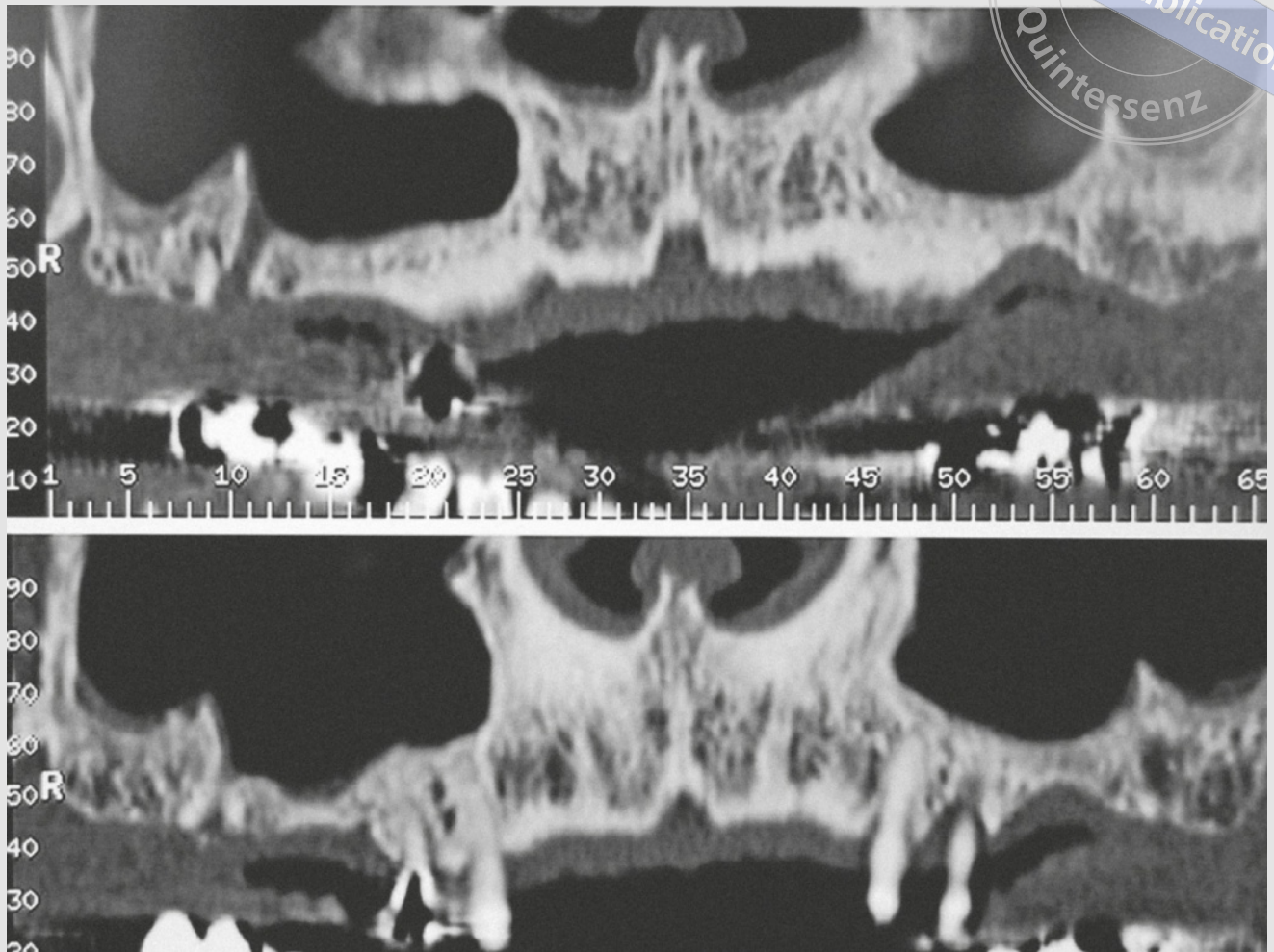


Fig 1-17 Initial view of the maxillary sinus (CBCT panoramic sections).

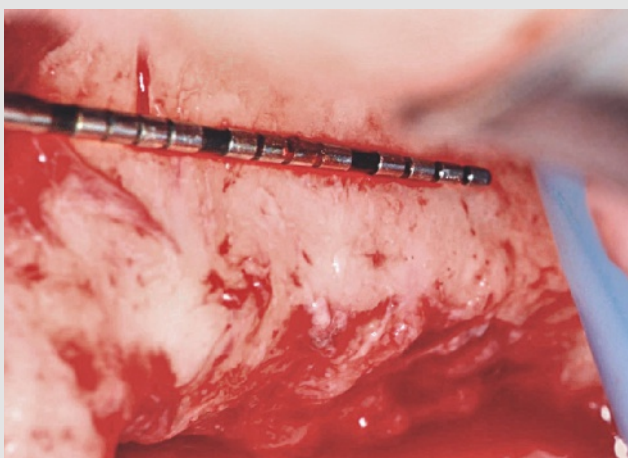


Fig 1-18 Measurements on the antral bone wall for the bony window positioning and design.

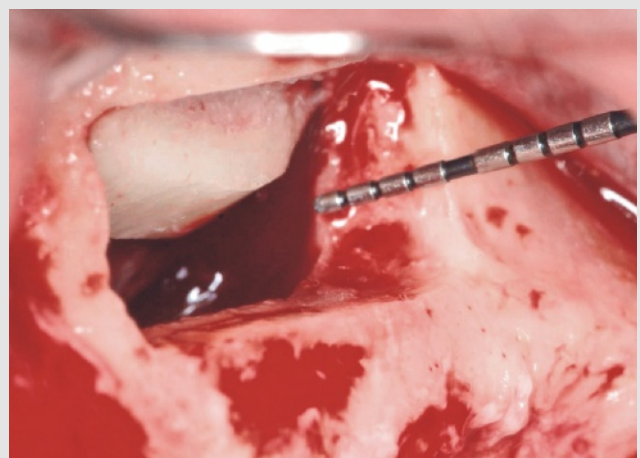


Fig 1-19 The bony window was pushed up and inward after membrane detachment and elevation.

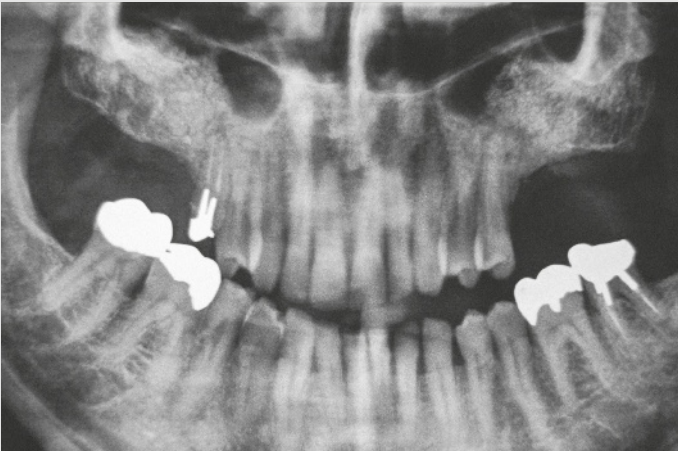


Fig 1-20 Panoramic radiographic control 4 months post-operatively (a bilateral sinus elevation has been performed).

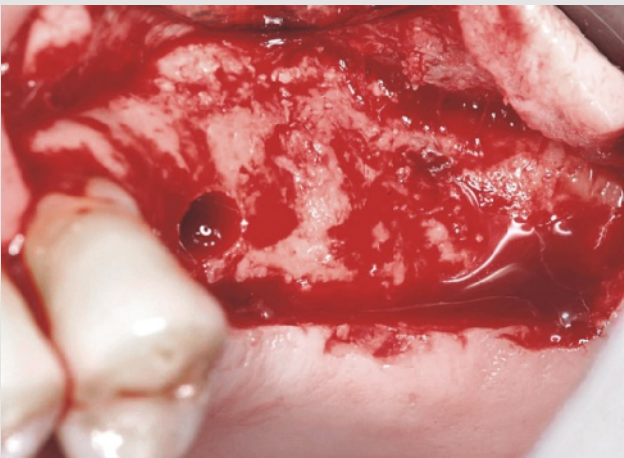


Fig 1-21 Preparation of the implant sites at 4 months post sinus augmentation; left side of the maxilla.

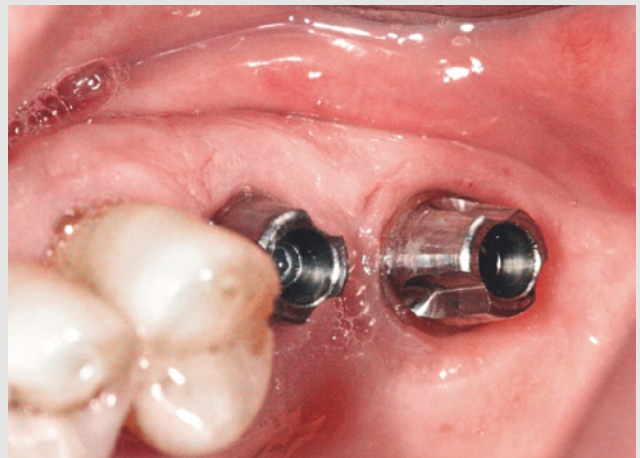


Fig 1-22 The prosthetic abutments for the two implants (Brånemark MkIII, 11.5 × 5 mm; Nobel Biocare).

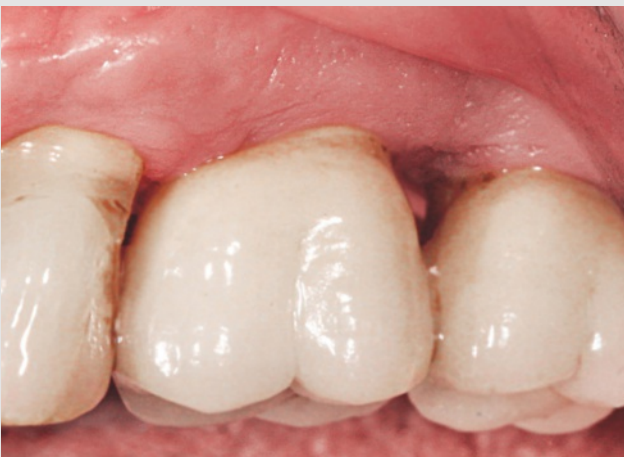

Fig 1-23 Final prosthetic restorations (courtesy of Dr B. Bufa-Louise, Private Practice, Marseille, France).

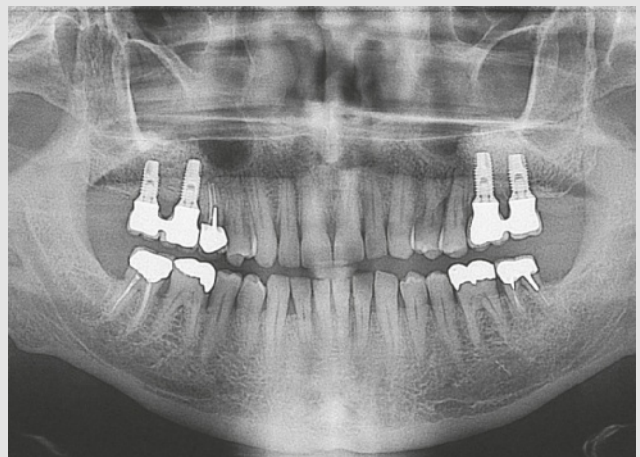


Fig 1-24 Panoramic radiographic control 1 year after completion of the treatment.

The crestal approach

The crestal approach consists of drilling the residual crestal bone up to the sinus membrane and performing a “blind” membrane elevation. Usually the implants are set in the same surgical session when using this technique (Figs 1-25 to 1-30).

Prerequisites for a predictable surgical outcome

Some clinicians may find sinus elevation difficult to contemplate, but this is likely because they are not familiar with the sinus anatomy; they may be mainly concerned with the teeth and oral environment. However, removing a maxillary first molar with a sinus relation, which is performed in everyday practice, can pose the same difficulties.

In this context, learning and understanding the anatomy of the maxillary sinus is probably the most important prerequisite in order to avoid complications and provide a predictable surgical outcome. In addition to this, thorough knowledge of the pathology, accurate interpretation of the radiographs, computed tomography/cone beam computed tomography (CT/CBCT) scans, as well as a high-performance instrumentation are required for a comprehensive and efficient management.

Thorough knowledge of the anatomical landmarks and the innervation and vascularization of the sinus enables dental clinicians to achieve good spatial orientation, and allows correct drawing of the bony window, predictable augmentation of the sinus membrane, and better control of crestal drilling if a lateral approach is contraindicated.

Crestal approach.

copyright by
not for publication
Quintessenz

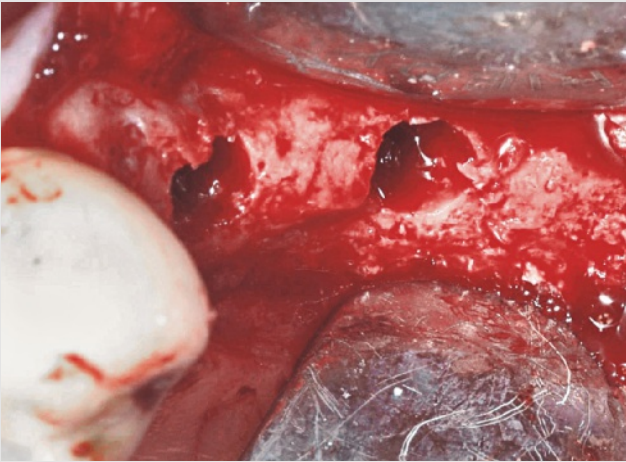


Fig 1-25 The glide holes were prepared after a small full-thickness flap elevation.

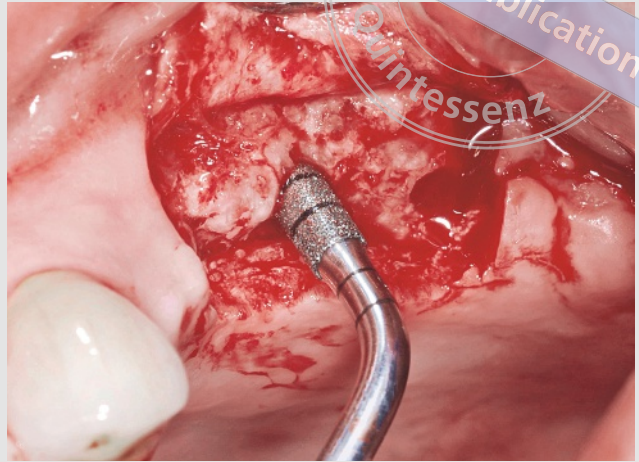


Fig 1-26 The implant site was drilled with nonaggressive ultrasonic devices up to the sinus membrane.

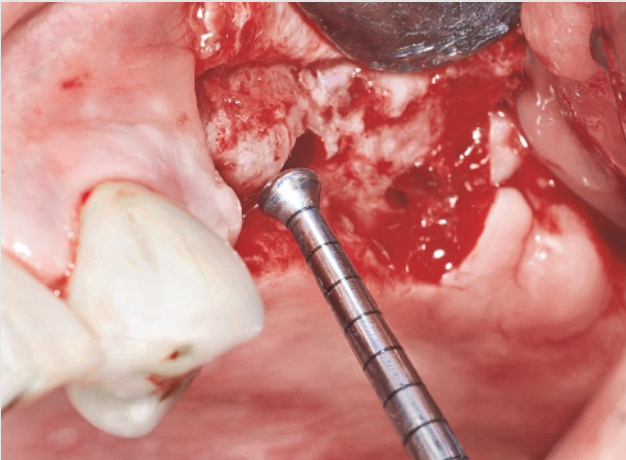


Fig 1-27 Hydrodynamic membrane detachment and elevation (Intralift TKW5 tip; Acteon).

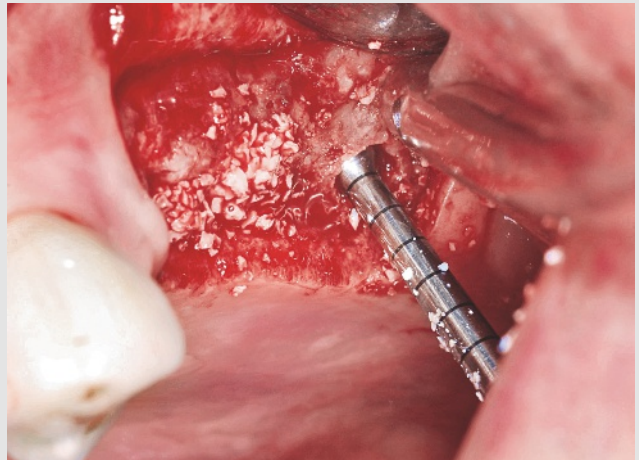

Fig 1-28 Bone graft material was placed inside the sinus through the implant path (small particles).

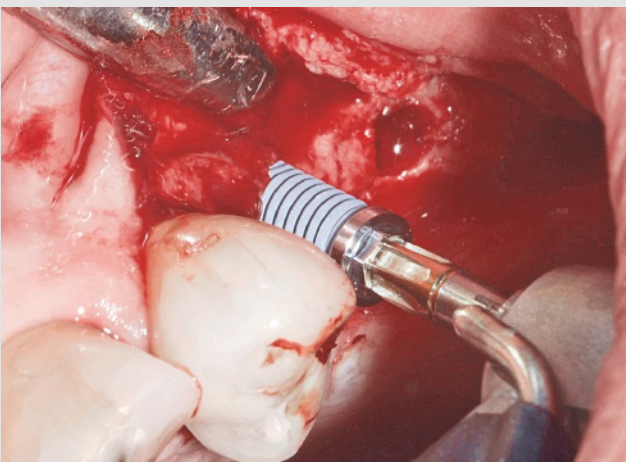


Fig 1-29 Placement of the first implant (Brånemark MkIII, 11.5 × 5 mm; Nobel Biocare).

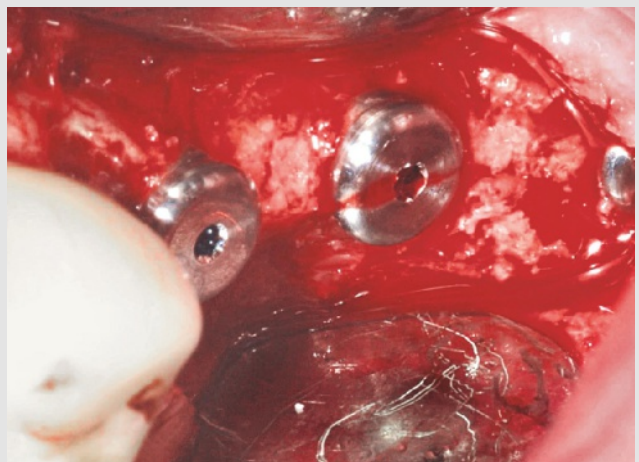
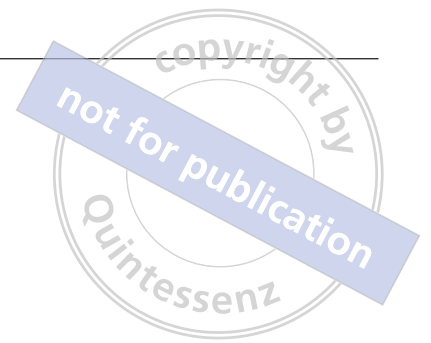

Fig 1-30 Three implants (Brånemark MkIII, 11.5 × 5 mm; Nobel Biocare) were placed and locked immediately before closure of the surgical site.



Index

A

anatomical landmarks 8, 12–28, 49, 73, 96
anatomy, sinus floor 8, 12, 17–19, 25, 46, 61, 72, 73, 77, 86, 94, 96, 103, 104
anesthesia 46
angiogenesis 43
angle 17, 25–26, 73, 96
antibiotics 46, 96, 103
anti-inflammatory 46, 96
antral artery 21–23, 46, 48–49, 96, 98, 102, 103
antral wall 6, 23–25, 30, 46, 48–50, 61
artery:
 alveolar antral 21–23, 46, 48–49, 96, 98, 102, 103
 infraorbital 21–22
 intraosseous 49, 103
 posterior superior alveolar 21–22, 103
aspergillosis 96, 103
autogenous bone 41–43
allograft 41, 44

B

balloon-assisted sinus floor elevation 30, 73–77
biocompatibility 41, 43
biomaterial 2, 4, 30, 41–44, 46, 55–56, 58, 61, 67, 68, 72, 73, 77, 81
bleeding 103
bone:
 defect 61, 69–70
 formation 41–43, 72
 graft 61–64, 94
 substitute 41, 46, 58, 67, 68, 73, 81
 wax 103

bony flap 61, 63, 66, 70
bony septum 12, 17–19, 25, 26, 46, 48–51, 73, 96, 103
bony window 3, 4, 6, 8, 17, 18, 24, 30–32, 36, 37, 42, 43, 46–51, 52–59, 62–70, 97, 101, 103, 104

C

chlorhexidine 96
collagen membrane 42, 44, 97, 100, 105
collagen sponge 77, 83
complications 8, 30, 73, 94, 96, 97, 103–109
cortical plate 21, 61
corticalization 12, 27
corticosteroids 96
corticotomy 21, 24, 31, 46, 48, 52, 103
crestal approach 2, 8, 12, 30, 34, 48, 72–94, 96, 97, 103
crestal height 77
cyst 96, 103, 104–108

D

delayed implant placement 2, 4, 6–7, 12, 46, 58
detachment, see sinus membrane elevation

E

edema 96, 103
elevation, see sinus membrane elevation
epistaxis 97

- F**
- full-thickness flap 9, 46–48, 53, 62, 79
- G**
- graft:
- allograft 41, 44
 - bone 20, 41, 61–66, 70, 73
 - composite 41
 - material 2, 3, 21, 41–43, 103
 - xenograft 43
- H**
- healing 21, 42, 43, 46, 58, 61, 72, 96, 103
- hematoma 96, 102–103
- hemorrhage 96, 102–103
- I**
- immediate implant placement 2, 4–7, 12, 27, 46, 72, 77, 96
- Implant Center 2 34–35
- implant length:
- regular 2, 72
 - short 2, 13
- implant placement:
- delayed 2, 4, 6–7, 12, 46, 58
 - immediate 2, 4–7, 12, 27, 46, 72, 77, 96
- incision line opening 103, 109
- infraorbital artery, *see* artery
- instruments 30–40
- burs 30, 31, 48, 61, 79, 104
 - chisels 30, 48, 73
 - curettes 30–33, 36, 46, 54, 58, 69, 97, 100
 - mallet 30, 73, 74
 - manual 2, 30–33, 61
 - mechanical 2, 30–33, 61
 - microscrews 30, 33, 64, 66–68
 - osteotome 30–32, 72–73, 94
 - pilot drill 72, 77, 83, 84
 - tips 9, 34, 36–40, 48–60, 65, 73, 77, 79–83, 92, 98, 103
 - trepine 30, 32, 72
 - ultrasonic 2, 9, 30, 34–40, 48, 52–58, 73, 77, 79, 102
- internal wall angle 17
- Intralift technique 77
- modified 83–91
- intraoperative complications 96, 97
- iodine radiocontrast solution 73
- J**
- Jensen classification 12, 42, 73
- L**
- lateral approach 2, 4, 12, 30, 34, 36, 42, 46–71, 72, 96, 97, 98, 103
- lateral wall 3, 43, 61
- angle 17
 - thickness 12, 24
- M**
- manual instruments 2, 30–33, 61
- material, *see* biomaterial
- meatotomy 103
- mechanical instruments 2, 30–33, 61
- mechanical technique 30–33, 61
- medial wall 26
- Meisinger Balloon Lift Control 30, 73–77
- membrane:
- barrier 42–44, 58, 61, 68, 70, 99, 100, 105
 - collagen 42, 44, 97, 100, 105
 - perforation 17–19, 73, 77, 96–101, 103, 105
 - resorbable 42, 58, 61, 70
 - synthetic 42, 44, 68, 97, 103
 - see also* sinus membrane
- mucoperiosteal flap 46, 65
- N**
- nasal obstruction 96
- O**
- osseointegration 41, 73, 103
- osseous window, *see* bony window
- osteoconductive 41
- osteotome 30–32, 72–73, 94
- osteotomy 12, 48, 73, 97, 103
- ostium 12, 26, 96, 103
- P**
- paresthesia 97
- pathology 8, 46, 96
- perforation 17–19, 73, 77, 96–101, 103, 105
- Physiolift, *see* Sinus Physiolift
- piezosurgery 17, 34–40, 46, 48, 52, 61, 77, 83, 86, 97, 103
- Piezotome 34–36, 39, 48, 61, 77, 83, 89
- pneumatic pressure 73, 77
- pneumatization 2, 17, 41

posterior superior alveolar artery 21–22, 103
postoperative care 96, 97
postoperative complications 97, 103–109
preoperative care 46, 72, 95–103
pressure:
 hydraulic 77, 83, 86
 hydrodynamic 9, 39, 40, 77, 81, 83, 89, 93
 pneumatic 73, 77
primary stability 72
prosthetic space 12, 20, 61, 65

R

radiocontrast solution 73, 86, 87
releasing incision 46, 47, 103
residual bone height 2, 12–16, 24, 26–28, 42, 46, 47,
 72, 73, 77, 94, 96, 103
resorbable membrane 42, 58, 61
rhinorrhea 103

S

septum, see bony septum
short implant 2, 13
simultaneous implant placement, see implant place-
 ment, immediate
sinus floor anatomy 12, 17–19, 25, 46, 61, 72, 73, 77,
 94, 96, 103, 104
sinus height 12, 26
sinus membrane:
 alteration 24, 26, 36, 73, 77, 86, 103
 elevation 1–10, 12, 17, 25, 26, 30, 42, 48, 58, 69,
 72, 76, 81, 97, 106
 integrity 4, 30, 42, 58, 63, 66, 72, 77, 80, 83, 86
 perforation 17–19, 73, 77, 96–101, 103, 105
 thickness 12, 26, 27–28

Sinus Physiolift 39, 40, 73, 86, 92–93
sinus walls:
 antral wall 6, 23, 24, 25, 30, 46, 48, 49–50, 58, 61
 internal wall 17, 26, 33, 73, 96
 lateral wall 3, 4, 12, 17, 21, 23, 26, 43, 46, 58, 61
 medial wall 26
sinus width 12, 25
sinus septum, see bony septum
sinusitis 27, 96, 97, 103
socket preservation 2, 3
Summers technique 30, 32, 72–73, 77
survival rate of implants 2, 41, 42, 43, 73, 94, 96, 97
suture 46, 58, 82, 90, 96, 97, 98, 99, 103
swelling 96, 103
synthetic membrane 42, 44, 68, 97, 103

T

two-stage procedure 2, 46, 58, 96, 104

U

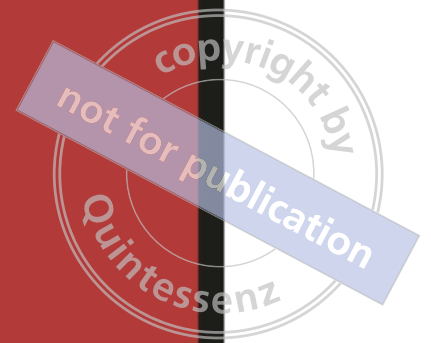ultrasonic instruments 2, 9, 30, 34–40, 48, 52–58, 73,
 77, 79, 102
ultrasonic technique 52–58

V

Valsalva maneuver 58, 72, 73, 97
vascularization 8, 12, 21–23, 25, 34, 43, 61
viral infection 96

W

wound dehiscence 17, 96



Sinus augmentation has become a routine surgical procedure to increase the height of the edentulous atrophied posterior maxilla. Numerous techniques have been used successfully, allowing a high survival rate of implants placed after sinus elevation. This book highlights the anatomical landmarks and describes, using clinical cases, the latest ultrasonic devices used for both lateral and crestal approaches, including their possible complications. With step-by-step clinical images, this book will help the clinician to make rational decisions for maxillary sinus augmentation, and to treat any complications that occur during surgery. This is an extremely accessible and up-to-date resource that every dentist should have in their office, for clinical guidance in their treatment planning or when performing sinus augmentation.

ISBN: 978-1-78698-018-2



9 781786 980182

<http://www.quintpub.co.uk>