

SURGICAL COMPLICATIONS IN ORAL IMPLANTOLOGY

Etiology, Prevention, and Management

Louie Al-Faraje, DDS

Founder and Director
California Implant Institute
San Diego, California

With contributions by

James L. Rutkowski, DMD, PhD

Christopher Church, MD



Quintessence Publishing Co, Inc

Chicago, Berlin, Tokyo, London, Paris, Milan, Barcelona,
Istanbul, Moscow, New Delhi, Prague, São Paulo, and Warsaw

CONTENTS

Dedication	<i>ix</i>
Contributors	<i>x</i>
Preface	<i>xi</i>
Acknowledgments	<i>xii</i>

Part I Identifying Preoperative Conditions That Could Lead to Complications

Complications

1	Inadequate or Excessive Vertical Restorative Space	2
2	Inadequate Horizontal Restorative Space	5
3	Limited Jaw Opening and Interarch Distance	10
4	Inadequate Alveolar Width for Optimal Buccolingual Positioning	11
5	Maxillary and Mandibular Tori	16

Part II Intraoperative Complications in Implant Placement

Complications

6	Incorrect Implant Angulation	20
7	Malalignment	24
8	Nerve Injury	25
9	Irregular or Narrow Alveolar Crest	30
10	Extensive Resorption of the Mandible	32
11	Curved Extraction Socket	33
12	Injury to Adjacent Teeth During Implant Placement	35
13	Preoperative Acute and Chronic Infections at the Implant Site	37
14	Retained Root Tips in the Implant Site	40
15	Bleeding	42
16	Overheating of the Bone During Drilling	49
17	Stripping of the Implant Site	51
18	Sinus Floor Perforation	52
19	Nasal Floor Perforation	56
20	Accidental Partial or Complete Displacement of Dental Implants into the Maxillary Sinus	58
21	Accidental Displacement of Dental Implants into the Maxillary Incisive Canal	60
22	Deep Implant Placement	62
23	Shallow Implant Placement	75
24	Complications in Flapless Implant Placement	77
25	Aspiration or Ingestion of Foreign Objects	80
26	Mandibular Bone Fracture	81
27	Implant Fracture	83
28	Excessive Torque During Insertion and Compression Necrosis	85
29	Inadequate Initial Stability	87

Part III Postoperative Complications

Complications

- 30** Postoperative Pain 96
- 31** Tissue Emphysema Induced by Dental Procedures 99
- 32** Incision Line Reopening 100
- 33** Cover Screw Exposure During the Healing Period 105
- 34** Bone Growth over the Cover Screw 106
- 35** Soft Tissue Growth Between Implant Platform and Cover Screw 107
- 36** Bone Loss or Thread Exposure During the Healing Period 108
- 37** Implant Mobility During Stage-Two Surgery 114
- 38** Implant Periapical Lesion (IPL) and Retrograde Peri-implantitis 116
- 39** Cement Left in the Pocket 118
- 40** Radiotherapy, Osteoradionecrosis, and Dental Implants 123
- 41** Shallow Vestibule Secondary to Ridge Augmentation 125
- 42** Medicolegal Issues 127

Part IV Complications Associated with Lateral Window Sinus Elevation

Preoperative Complications

- 43** Preoperative Acute Sinusitis 135
- 44** Preoperative Chronic Sinusitis 136
- 45** Preoperative Fungal Sinusitis 138
- 46** Preoperative Cystic Structures and Mucocoeles 140
- 47** Other Preoperative Sinus Lesions 142

Intraoperative Complications

- 48** Hematoma During Anesthesia 152
- 49** Bleeding During Incision and Flap Reflection 152
- 50** Bleeding During Osteotomy 153
- 51** Damage to Adjacent Dentition 153
- 52** Perforation of the Sinus Membrane During Osteotomy 153
- 53** Perforation of the Sinus Membrane During Elevation 154
- 54** Incomplete Elevation 161
- 55** Bleeding During Membrane Elevation 162
- 56** Fracture of the Residual Alveolar Ridge 162
- 57** Excessive Elevation of the Membrane 162
- 58** Presence of a Mucus Retention Cyst 163
- 59** Blockage of the Maxillary Ostium 164
- 60** Unstable Implants 164

Early Postoperative Complications

- 61** Wound Dehiscence 164
- 62** Acute Graft Infection/Sinusitis 165
- 63** Exposure of the Bone Graft and/or Barrier Membrane 166
- 64** Sinus Congestion 166
- 66** Early Implant Migration into the Sinus Cavity 166

Late Postoperative Complications

- 66** Insufficient Quality and/or Quantity of Healed Graft 167
- 67** Implant Failure in the Augmented Sinus 167
- 68** Chronic Infection/Sinusitis 168
- 69** Infection of All Paranasal Sinuses/Intracranial Cavity 169
- 70** Delayed Implant Migration into the Sinus Cavity 169
- 71** Sinus Aspergillosis 169

Part V Pharmacology: Prevention and Management of Pain, Infection, and Drug-Related Complications

Complications

- 72** Intra- and Postoperative Infection 175
- 73** Intra- and Postoperative Pain 184
- 74** Bisphosphonate-Related Osteonecrosis of the Jaw 193
- 75** Bleeding Problems in Patients Taking Anticoagulants or Antiplatelet Agents 195


Appendices

- A** Implant Treatment Protocol 202
- B** Consent Forms 209
- C** Postoperative Instructions 225

Index 227

DEDICATION

To Abu al-Qasim Al-Zahrawi (aka Abulcasis), 936–1013 CE



Page from a 1531 Latin translation by Peter Argellata of Al-Zahrawi's treatise on surgical and medical instruments.

A pioneer in all fields of surgery, Al-Zahrawi conceived and developed innumerable surgical techniques and instruments and, in 1000 CE, published the first surgical encyclopedia, *Kitab Al Tasrif (The Method of Medicine)*, which spanned 30 volumes. For his monumental accomplishments and contributions to surgery, he earned the title Father of Modern Surgery. His way of thinking and his practice of surgery inspired many subsequent surgeons to achieve greatness and provided a beacon of light in the dark ages of Europe. In his many papers and manuals, he describes various operations and procedures that had never before been recorded. He wrote detailed descriptions of many surgical techniques, including cautery and wound management. Some have described him as the first plastic surgeon, notably for his attention to and methods of incision and use of silk thread suture to achieve good cosmesis. He devised about 200 surgical instruments, among them the surgical needle, scalpels, curettes, retractors, spoons, sounds, hooks, rods, and specula.

The street in Córdoba where his house still stands is named Calle Abulcasis in his memory. In 1977, the Spanish Tourist Board commemorated it in his honor with a bronze plaque that reads: "This was the house where lived Abu al-Qasim Al-Zahrawi."

CONTRIBUTORS

Christopher Church, MD

Director

Loma Linda Sinus and Allergy Center

Associate Professor

Department of Otolaryngology–Head and Neck Surgery

Loma Linda University School of Medicine

Loma Linda, California

James L. Rutkowski, DMD, PhD

Clinical Instructor

Department of Restorative Dentistry

School of Dental Medicine

University at Buffalo

The State University of New York

Buffalo, New York

Private Practice

Clarion, Pennsylvania

PREFACE

The use of dental implants to restore missing teeth has steadily increased over the past three decades. It is perhaps not surprising, then, that the number of implant-related complications has grown as well. Numerous clinical studies involving dental implants have revealed encouraging outcomes; however, there is an element of risk associated with all clinical procedures, and these encouraging results may have given rise to unrealistic expectations. Despite careful planning, there is always a potential for surgical complications. Nevertheless, carrying out routine tasks with care and attention, choosing minimally invasive techniques when indicated, recognizing evidence of a developing problem, and giving prompt attention will reduce postoperative complications.

The successful outcome of any surgical procedure requires attention to a series of patient-related and procedure-dependent parameters. Sound knowledge of surgical anatomy and experience and training in the fundamentals of internal medicine are important prerequisites for predictable implant surgery. Also, adequate presurgical planning, appropriate quality and quantity of available bone, a well-executed surgical technique, good primary stability, a sufficient healing period, and detailed postoperative instructions are all factors that play a vital role in the success of dental implant surgery and osseointegration. Aging, changing health conditions, wear and tear, and inadequate professional maintenance are important variables influencing prognosis.

This book is designed as a self-instruction guide to the diagnosis and management of surgery-related complications and to the development of a protocol that allows for the early detection of potential surgical complications and how to avoid them. It is a well-documented fact that early detection of complications that are amenable to rescue therapies may reverse the fate of a failing implant or bone grafting procedure.

The evidence-based methods of complications management described in this book are not meant to preclude the clinical judgment of experienced clinicians but rather should be applied to either support or prompt them to rethink their chosen methods of therapy on the basis of existing evidence.

ACKNOWLEDGMENTS

I would like to express sincere gratitude to my parents, Omar Al-Faraje and Nadia Al-Rifai, for their extraordinary sacrifices for too many years. Thank you for your unconditional love and support.

Also to my wife Rana, my lifelong companion and “book widow.” Her support was invaluable as I was hunched over my computer, sometimes for 12 hours a day. And to our children—Nadia, Omar, and Tim—who contributed immensely to this book by sacrificing their precious time with “Papa.”

In addition, I would like to thank my teachers at each of the medical institutions I attended. I was indeed fortunate to have had outstanding anatomical, clinical, and surgical training at the medical institutes in Russia, the Ukraine, and the United States.

Three special individuals have profoundly influenced my career:

Dr Nizar Al-Tair, my dental mentor, who spent countless hours challenging my knowledge and skills to deliver excellence and to be my best.

Dr Igor Persidsky, who taught me how to connect patients' medical problems with their dental needs and to think like a dental surgeon with internal medicine in mind. I treasure our years of friendship.

Dr Dewhirst Floyd, who gave me a helping hand and believed in me. This book would not have seen the light without his support during my early years in the dental field.

Finally, I would like to thank all of my students at the California Implant Institute. It is always a pleasure and an honor to share with you my knowledge and expertise in implant dentistry. For the last few years, my greatest professional joy has been interacting with my students and colleagues at the California Implant Institute.

I also would like to express my gratitude to Dr Christopher Church and Dr James Rutkowski for their contributions to this textbook.

Special thanks to Lisa Bywaters and her editorial team at Quintessence Publishing Company. Their tremendous support throughout the project allowed the creation of this modern, easy-to-consult textbook.

PART 1

Identifying Preoperative Conditions That Could Lead to Complications

Complications

- 1 Inadequate or Excessive Vertical Restorative Space
- 2 Inadequate Horizontal Restorative Space
- 3 Limited Jaw Opening and Interarch Distance
- 4 Inadequate Alveolar Width for Optimal Buccolingual Positioning
- 5 Maxillary and Mandibular Tori

COMPLICATION 6

Incorrect Implant Angulation

The implant must be angulated correctly in the buccolingual and mesiodistal planes for optimum function and esthetics.

Buccolingual angulation

Endosseous root-form implants distribute occlusal loads most effectively when forces are applied in an axial direction. An angulation of 15 degrees or less is considered acceptable. Even natural teeth are not straight, but rather perpendicular to the *curve of Wilson*, the lateral curve of the occlusal table formed by the inclination of the posterior teeth (Fig 2-1). However, as implant angulation approaches or exceeds 25 degrees, the supporting bone is severely compromised through transmission of occlusal forces (Fig 2-2a). Moreover, if an implant is inclined buccolingually and the prosthetic reconstruction is offset relative to the implant head for improved occlusion and/or esthetics, the inclination will introduce a bending moment on the implant and will lead to a few potential problems.

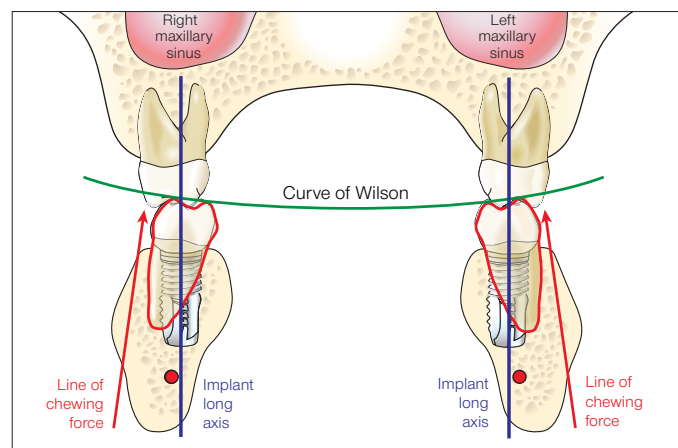


Fig 2-1 Natural posterior teeth are perpendicular to the curve of Wilson. In order for posterior implants to be aligned with the direction of chewing forces, they should also be positioned perpendicular to the curve of Wilson; however, vertical placement is acceptable because it is a minimal deviation from the direction of chewing forces.

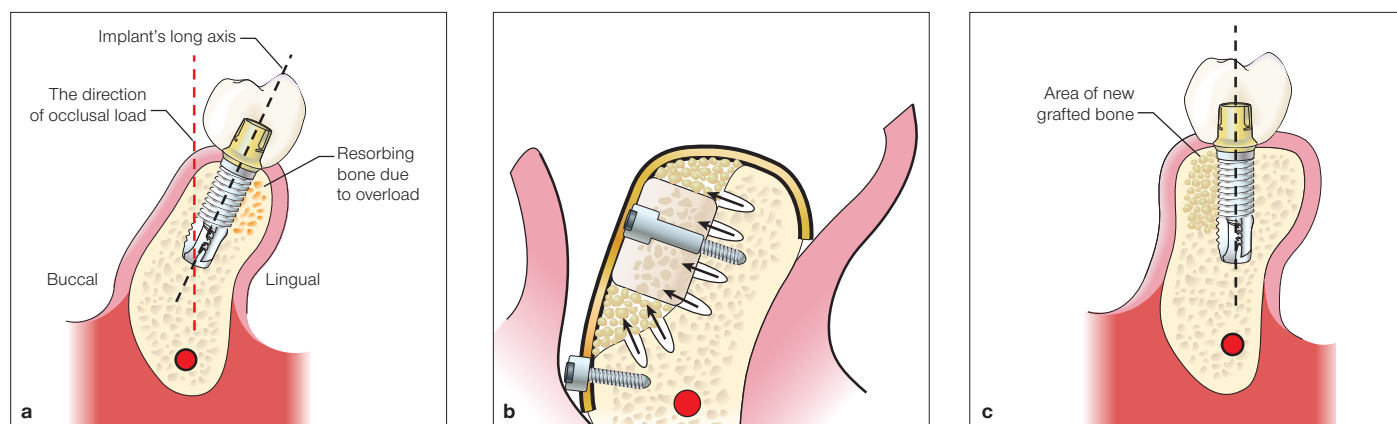


Fig 2-2 (a) Buccal bone resorption does not justify implant placement with severe lingual angulation (ie, greater than 15 degrees), which potentially leads to many problems. (b and c) The appropriate solution is ridge augmentation using a bone grafting procedure to allow proper implant placement.

Off-axis loading

Potential biomechanical problems of an excessive lingual trajectory (see Fig 2-2a) include:

- Restoration fracture
- Retaining screw fracture
- Abutment fracture
- Implant body fracture
- Osseous destruction because of unfavorable loading
- Plaque accumulation under ridge lap pontics

Placement of an overly inclined implant is not an acceptable practice, especially for single-unit restorations. If it is not possible to place an implant with an angulation of 15 degrees or less, the treatment plan should be aborted and the implant placed in a different location, or implant placement should be delayed and the area grafted using techniques such as guided bone regeneration (GBR), block grafting (Fig 2-2b), or ridge splitting, to allow optimum buccolingual angulation (Fig 2-2c).

Mesiodistal angulation

Natural teeth are perpendicular to the *curve of Spee*, the anteroposterior curve formed by the cusp tips of the posterior teeth (Fig 2-3).

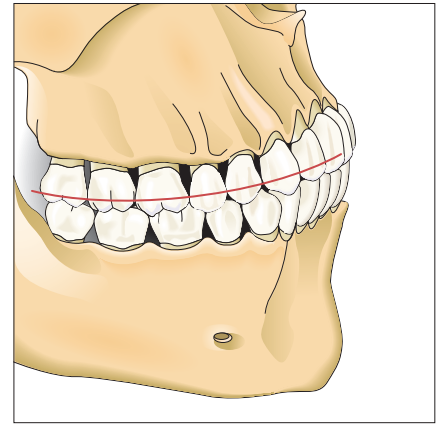


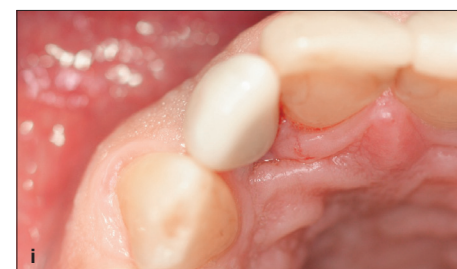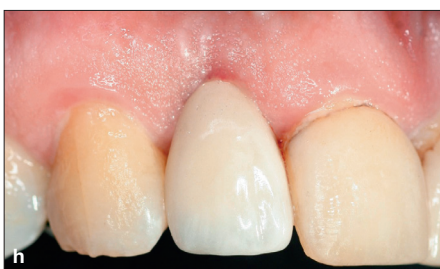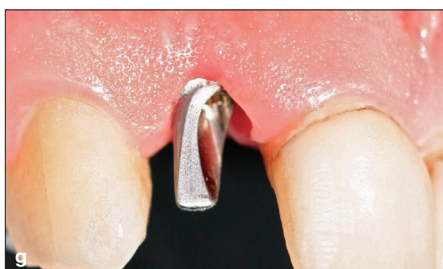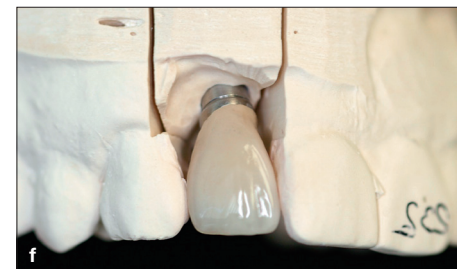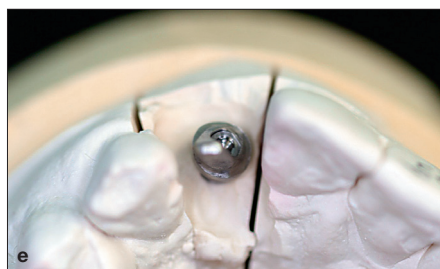
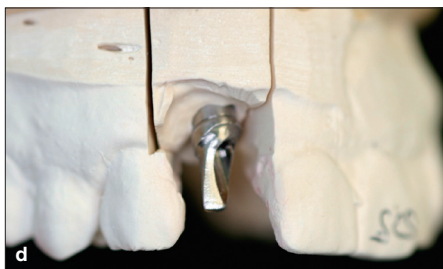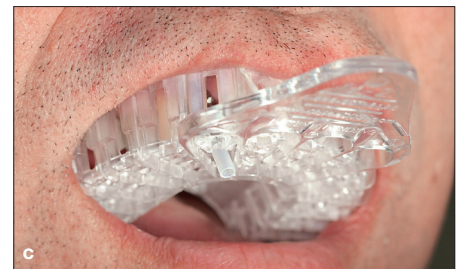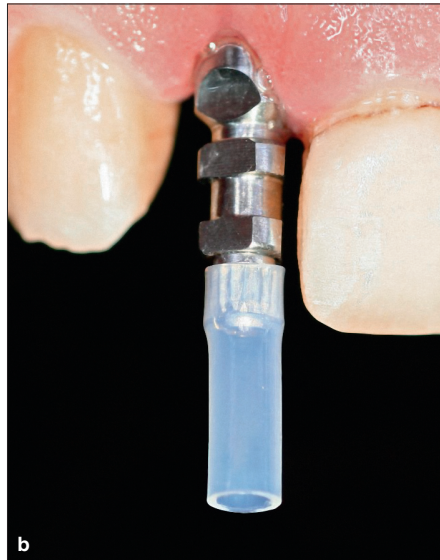
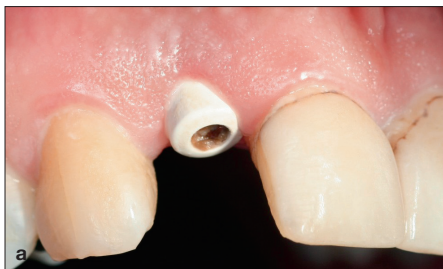Fig 2-3 Curve of Spee.

Single implant cases

In single implant cases, excessive mesiodistal angulation should be avoided. The use of an angled abutment can compensate for slight inclinations (Fig 2-4); however, if the inclination is too severe, the implant should be removed and reinserted in a more upright position, either immediately or after a period of osseous healing.

To prevent excessive angulation, the surgeon should evaluate the position of the osteotomy after use of the pilot drill by placing a parallel pin in the pilot hole and taking a radiograph. If the angulation is not satisfactory, a Lindemann side-cutting drill can be used to adjust the angulation before continuing preparation of the implant site (Fig 2-5).

Fig 2-4 (a to i) The implant to replace the missing right lateral incisor was placed with imperfect angulation. However, the mesial inclination is mild, and the use of an angled abutment compensated for the inclination.



COMPLICATION 10**Extensive Resorption of the Mandible**

As noted in complication 8, the mental foramen may be positioned on the crest of the ridge in a severely resorbed mandible. Care should be taken to protect the mental nerve by placing the crestal incision lingually; however, if the resorption is extensive and the mental foramina cannot be clearly identified on the panoramic radiograph or CT scan, a flapless implant insertion protocol is recommended to avoid damage to the mental nerve or any of its branches. This technique is shown in Fig 2-23.

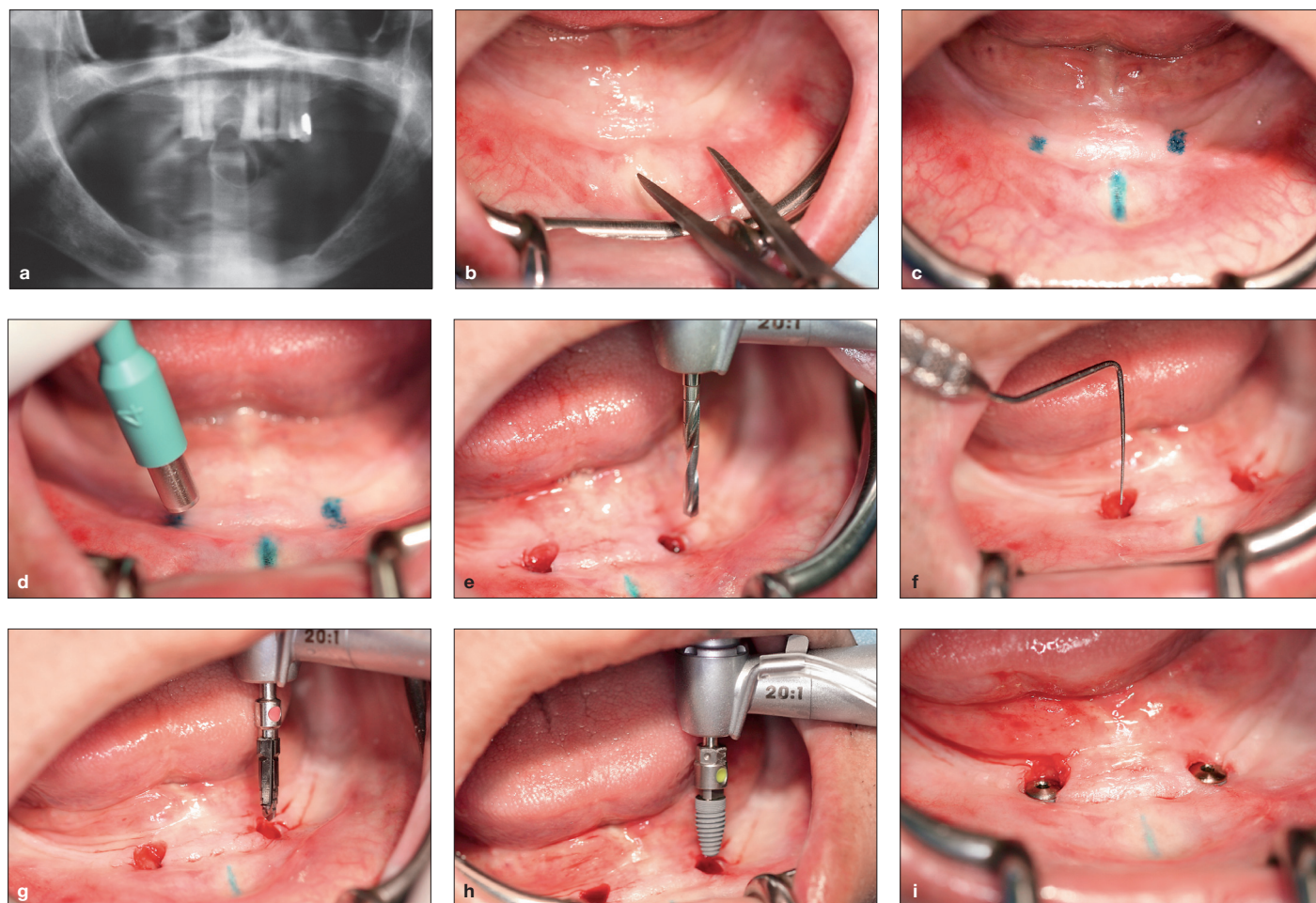


Fig 2-23 (a) The panoramic radiograph did not reveal the exact location of the mental foramina in this case. A decision was made to place the implants using a flapless insertion protocol to avoid transecting the mental nerve during incision. (b and c) The alveolar bone within 12 mm on each side of the midline was established as a low-risk area for implant placement. (d) A disposable tissue punch was used to access the crestal bone. (e) A 2.0-mm pilot drill is used to initiate the implant osteotomies. (f) After the use of each drill, a periodontal probe was used to verify that the osteotomy was completely within the alveolar ridge. (g) The implant osteotomy was enlarged as needed. (h) The implants were placed. (i) Healing screws are placed for the two-stage insertion protocol. The patient was treatment planned for a ball-retained overdenture after excessive vertical restorative space was identified. O-ring caps were incorporated into the denture to disengage the ball attachments before vertical cantilever forces became excessive.

COMPLICATION 11

Curved Extraction Socket

It is challenging to place an immediate implant in an ideal position into a socket after extracting a tooth with significant root curvature (Fig 2-24a). The thick palatal or lingual wall of the socket tends to direct the rotating drill toward the thinner buccal plate, placing the osteotomy and, subsequently, the implant in an unfavorable and unesthetic location. Perforation of the buccal wall of the socket may also result.

This difficulty can be overcome using a Lindemann side-cutting drill (Fig 2-24b). The drill should be placed in the socket first, then the motor activated, and a groove cut in the lingual socket wall (Figs 2-24c), facilitating movement of the subsequent implant drills in the appropriate direction for correct osteotomy positioning (Fig 2-24d). This technique is often necessary when placing immediate implants in maxillary anterior and mandibular premolar and anterior sites. Figure 2-25 shows a case of immediate implant surgery in a curved socket.

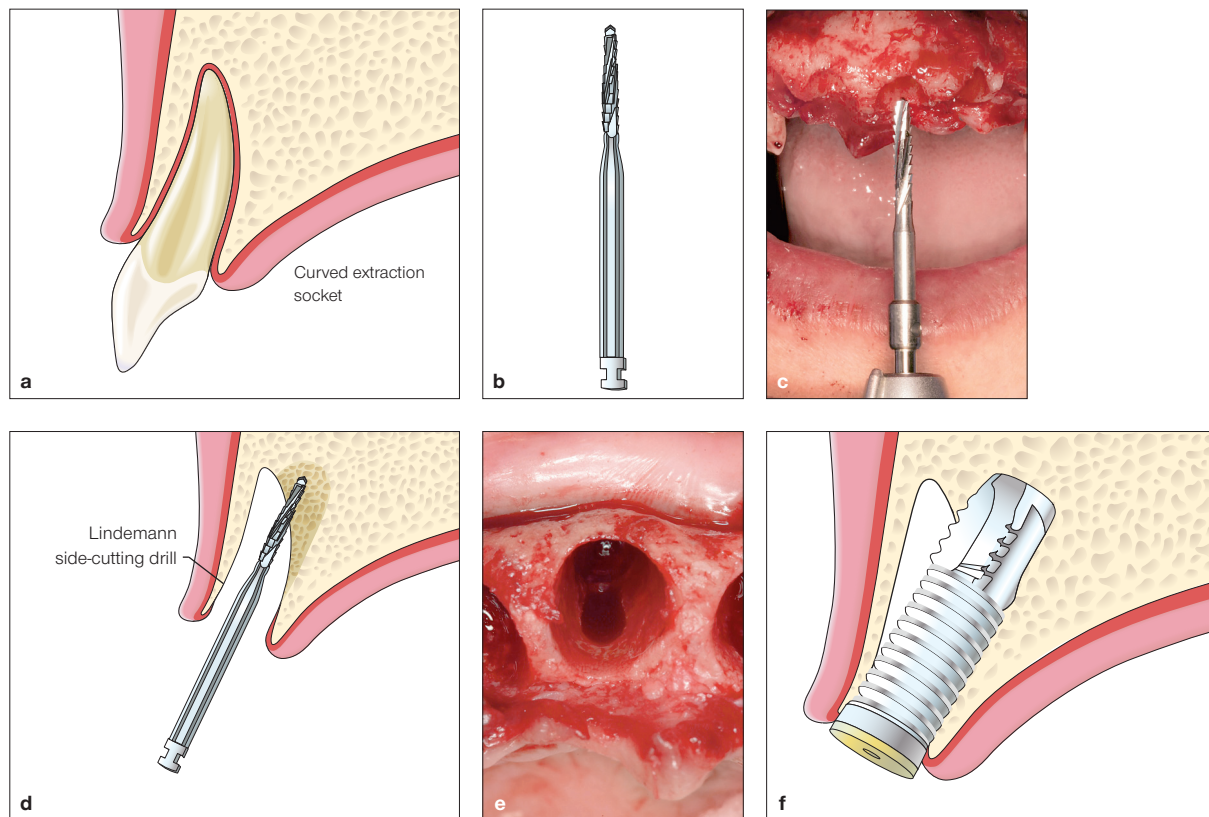
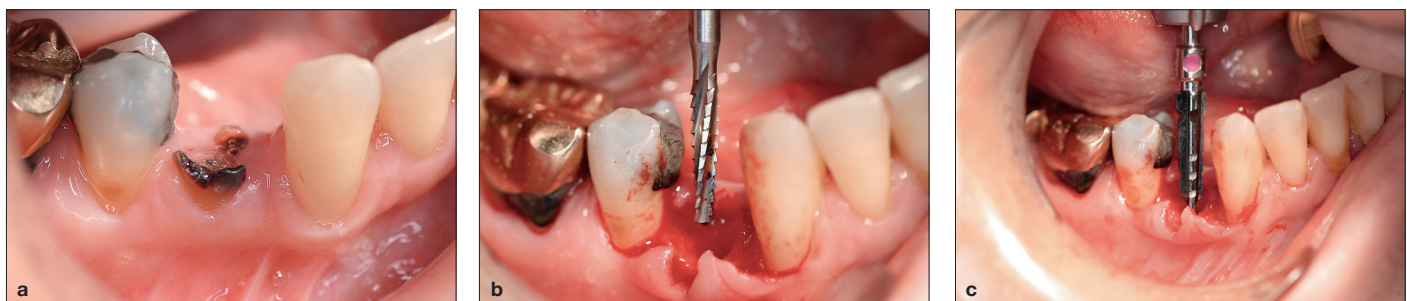

Fig 2-24 (a) A curved socket presents a challenge for ideal immediate implant placement because the thick palatal/lingual wall of the socket tends to redirect the drill toward the thin buccal plate. (b and c) The use of a Lindemann side-cutting drill enables the creation of a depression or groove in the palatal/lingual side. (d) Cross-sectional view of the redirection of the socket using the Lindemann drill. (e) Clinical view of the groove created by the Lindemann drill. (f) Placement of the implant in the proper direction in a curved socket.



Figs 2-25a to 2-25c (a) Immediate implant surgery in a curved mandibular premolar socket. (b) A Lindemann drill was used to create a groove in the lingual surface of the alveolus. (c) Subsequent drills are used to further redirect the osteotomy from its natural path down the curved lingual wall of the socket, thus avoiding perforation of the buccal plate and misalignment of the implant.

Lateral Window Sinus Elevation Surgical Protocol

Before discussing the complications that may occur during the lateral window sinus elevation, it is important to present the surgical protocol that should be followed to minimize the risk of complications.

The lateral window sinus elevation surgical protocol consists of the following eight steps (Fig 4-19):

1. Anesthesia

2. Incision and full-thickness flap reflection

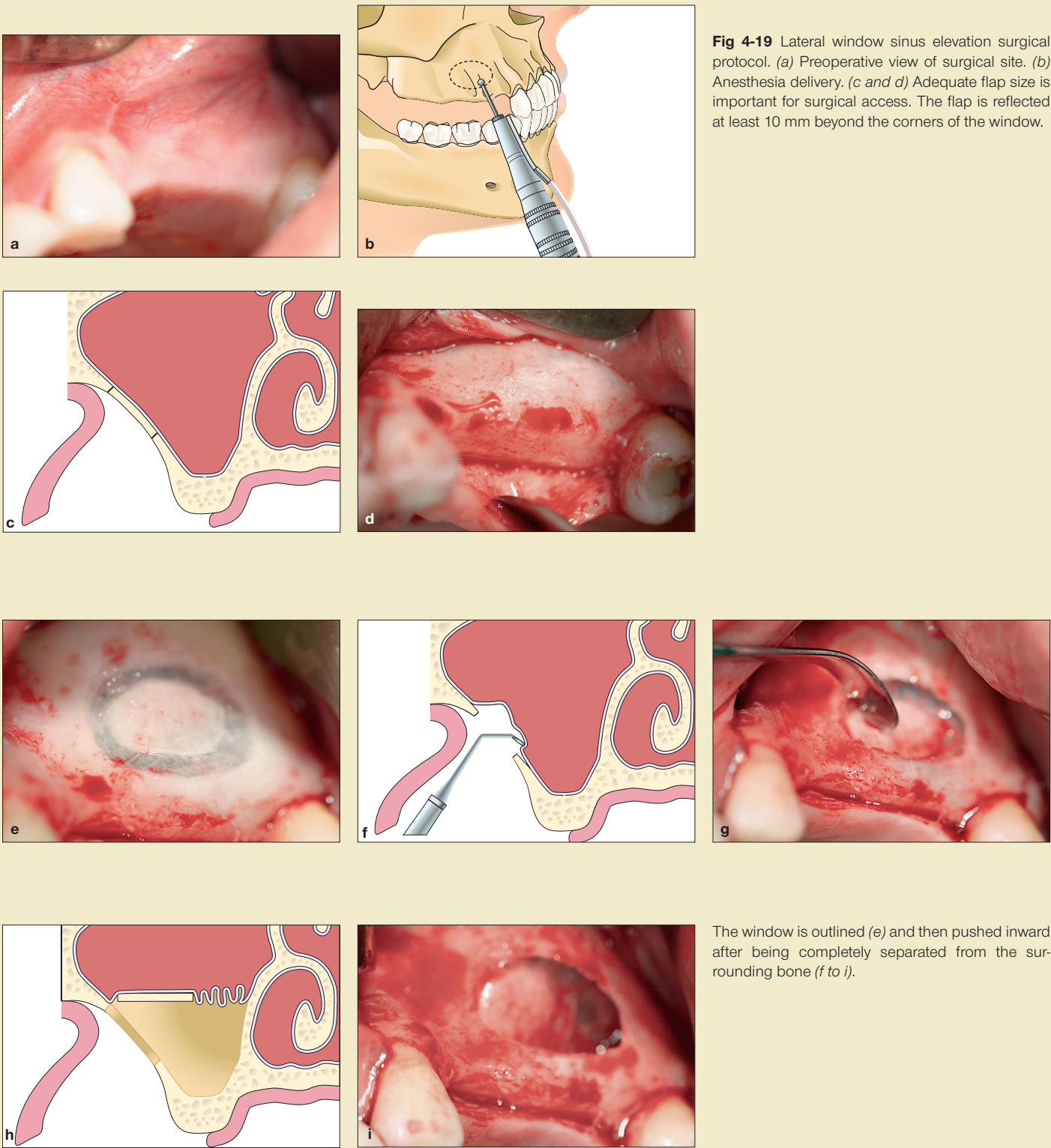
3. Osteotomy and window infractionure or removal

4. Sinus membrane elevation
5. Bone graft placement

6. Incision closure

7. Postoperative provisionalization

8. Postoperative instructions and care



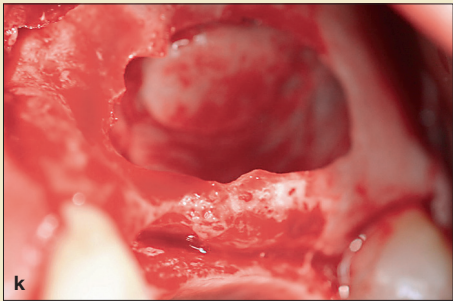
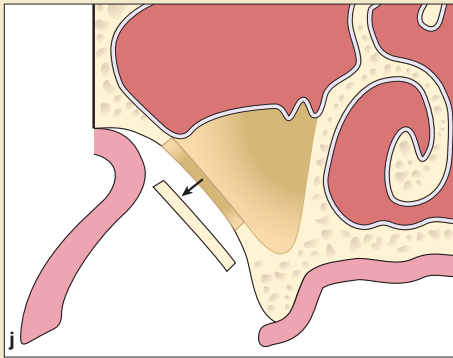
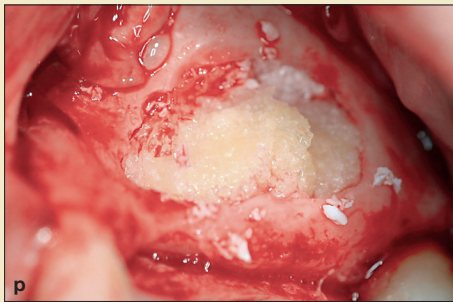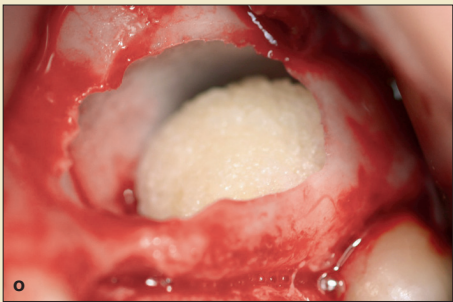
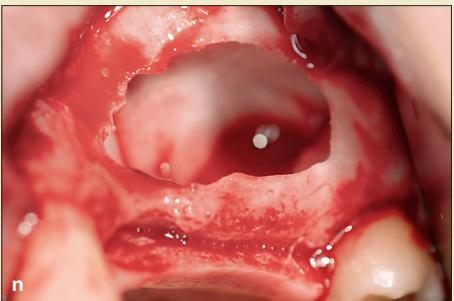

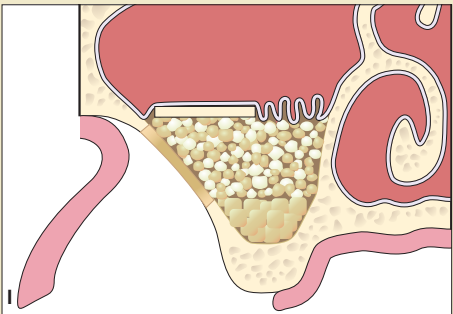


Fig 4-19 cont (*j and k*) Alternatively, the surgeon may elect to remove the bone flap (eg, when the buccolingual dimensions of the sinus are narrow).



The bone graft material is placed (*l* to *r*), the flap is sutured (*s*), and the area is left to heal for a period of 4 to 9 months (depending on the volume and type of bone graft materials used) before implant placement (*t* and *u*).

