

Challenging Nature Challenging Nature Challenging Nature Challenging Nature

Challenging Nature Challenging Nature Challenging Nature Challenging Nature

Challenging Nature Challenging Nature Challenging Nature Challenging Nature

Paulo Kano

Challenging Nature Challenging Nature Challenging Nature Challenging Nature
Challenging

Challenging Nature Challenging Nature Challenging Nature Challenging Nature
Nature

Challenging Nature Challenging Nature Challenging Nature Challenging Nature
Wax-Up Techniques
in Aesthetics and Functional Occlusion

 QUINTESSENCE PUBLISHING

London, Berlin, Chicago, Tokyo, Barcelona, Beijing, Istanbul, Milan,
Moscow, New Delhi, Paris, Prague, São Paulo, Seoul and Warsaw

Foreword

I have to say that I have been very proud to be a Brazilian citizen since I was a kid. There is good reason for this. During my childhood, Pelé, Garrincha, and other great players spell bound and amazed the world with their “dream team” soccer style. At the same time, Tom Jobim (one of the most brilliant geniuses in popular music of all times) and so many other Brazilian musicians and composers astounded the world with the bossa nova sound. My pride increased when I first saw Rio de Janeiro (I will never forget that day—I understood why it was called wonderful city), as well as other beautiful Brazilian cities. As a professor at the university, I have had the opportunity to become familiar with many outstanding dental schools in Brazil and make contacts with so many colleagues, professors, and dental technicians in prosthodontics. These connections make me very happy about the career I chose. In fact, in Brazil, there are so many talented people in so many different industries that it could make some people jealous. Recently in Los Angeles, I was happy to see the tarmac full of Brazilian designed and constructed airplanes by Embraer. When I got back to Santos on the coast of Brazil, I had the privilege of driving on one of the most beautiful and modern roads in the world, and my pride grew because it was constructed by a Brazilian company. Although it is true that I have been ashamed of my country at times, the good feeling always returns eventually.

Well, readers may say, “what do all these things have to do with dentistry?” The answer is that Paulo Kano and his book are responsible for part of my happiness of being a Brazilian citizen. Certainly, he is a talented dentist and one of the foremost dental technicians in the world (although these accomplishments are difficult to compare to each other). In addition, he is an approachable guy that developed a simple technique and has honed the ability to teach one of the most complex issues in our profession: functional wax-up of teeth. In recent years, Paulo Kano changed the way dental technicians and dentists sculpt teeth. This is a major breakthrough in the dental profession. Now, with this beautiful book, Dr Kano makes me remember my childhood and, just like Pelé, Garrincha, Tom Jobim, Chico Buarque, Carlos Drummond de Andrade and so many others, to inspire once again my pride of being a Brazilian citizen. Thus, read this book and understand the pride of being a Brazilian citizen.

Luiz Narciso Baratieri
Titular Professor, Department of Restorative Dentistry
Federal University of Santa Catarina, Florianópolis, SC, Brazil.

Preface

During much of my life, I dreamed about making a book. I dreamed and tried to make it happen many times. I dreamed and gave up every time until I met the famous Prof Luiz Narciso Baratieri, a simple man with a pleasant disposition. Although I had never talked with him about it, he realized in a moment that I wanted to do this project and soon began to push me toward it. Almost every day he called me: “Paulo, you have to write this book.” I was convinced that this was impossible, but he would call again to say, “Paulo, you have to write this book.”

Surprisingly, as time went by and contrary to expectation, he only redoubled his efforts and began to call two to three times a day to say “Paulo, this is the right moment; please write this book.”

Due to his insistence, I began to believe again that it would be possible, and so I decided to do it. It took many hours, days, months, and years of hard work, as well as confronting the fear of not having a book and actually doing it. I was afraid that the material was not of good quality and would disappoint my colleagues. On the other hand, the fear of not being capable of writing and thus disappointing my

great friend and supporter was even worse. Against all odds, I decided to start the project, but several times I considered giving up and ignoring what I had prepared. However, every time this happened Prof Baratieri was there to say, “Paulo, do not give up, you will succeed”.

And we (Prof Baratieri and I), finally did it. Here is the book.

Whether it is good, beautiful, or well done or there are some errors or clinical cases that were not developed like the reader would like, maybe it does not matter. For me, the most important thing is that it is done, and in this way I can share with you what I have learned in my life.

I tried to make this book simple, using the photographic sequences to work in tandem. Thus, I suggest that readers examine the figures one by one and then read the respective legends. In addition, the exercises included here must be completed by some practical courses. In this way, the wax-up of posterior teeth can be refined by all professionals.

Acknowledgments

To my dear friend and supporter, Prof Dr Luiz Narciso Baratieri, for believing in my work; for his ideas, respect, support; and for being a constant example of perseverance and devotion. Thank you to his wife, Prof Naira Maria Baratieri, and to his children, Carolina, Gabriel, and Pedro, because they make me believe that “to share a dream is what makes it come true.”

To Alice Kano, my wife, for her continuous support.

To Renata Gondo, Leticia Durand, and Jakeline Guimarães, for their support during the preparation of this book. Thank you for their dedication that was fundamental to the realization of this book.

To Luis Schilichting, Renan Belli, and Lessandro Machry, for their collaboration and their outstanding pictures.

To Prof Dr Jorge Perdigão for providing some images for this book.

To Prof Gláucia Santos Zimmerman for her collaboration in the clinical case.

To Mr Rui Santos, editor and great supporter, for helping my dream come true and for his patience and suggestions.

To my parents (Yoshihiko and Yukie Kano), my father- and mother-in-law (Yasuki and Satie Fukushima), my brothers (Aldo, Alcides, Solange, and Carlos). To my nephew Cleyton Kano, who helps me in my clinical practice. To my brother-in-law and friend, Edson Saito, for showing me the first steps in the art of dental ceramics.

To my friends Cirleide, Fernando, Alexandro (Jiló), and Alex-Sandro for constant support and for making my professional career more fun and productive.

Thank you to Paulo Tychi, Juliana Rocha, Adelize Muniz, Luiz Audi, José Bazone Filho, Maurício Watanabe, Elisabeth Kurkdjian, Silvia Helena

Barbosa, Celita Carniel, Marcos Oliveira, Marcelo Oliveira, Reinaldo Fraga, Marcos Celestrino, Robson Mendrot, Maria Helena Moura, Ciro Scarso, Luigi Ferrante, Lauro de Freitas Junior, Raul Morihashi, Júlio Yamanoshi, Mario Katsuki, Márcio Sgorlon, Miller Paiva Renata Matos, Nelson Hassui (in memorian), Marie Hassui, Antonio Hassui, and Newton Debellis for their friendship and support in the clinical courses.

To friends and professionals that help me continue to in my professional growth: Prof Luiz Narciso Baratieri, Herbert Mendes, Olympio Faissol Pinto, Tetsuo Saito, Ney Zapponi, Jorge Tamake, Glaucia Tamake, Antonio Salazar Fonseca, Limírio de Oliveira Jr, Admir Belmonte Gavira, and Humberto Cerruti.

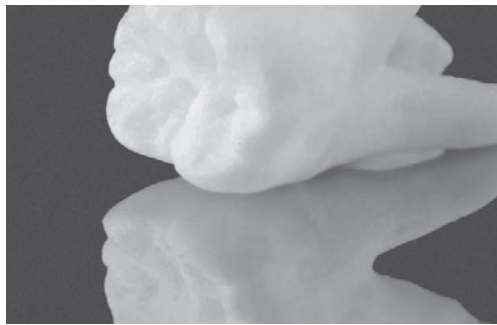
To friends and colleagues at work, Joao Salvador, José Carlos Romani, Nelson Bergamini, Carlos Maranghello, Márcia Gonçalves, José Scarso Filho, Francisco Todescan, Eglas Bernardes da Silva, Rosimeire Marques, Carlos Coppos, Waldemar Motta Neto, Rodolfo Alba Junior, João Vaiano, Luis Rei, Victor do Carmo, Osvaldo de Souza, Glécio Vaz de Campos among many myriad others I would like to cite.

To all dental technicians in prosthodontics, dentists, and students that were my pupils: because of you I understand human nature better and have learned more about this profession.

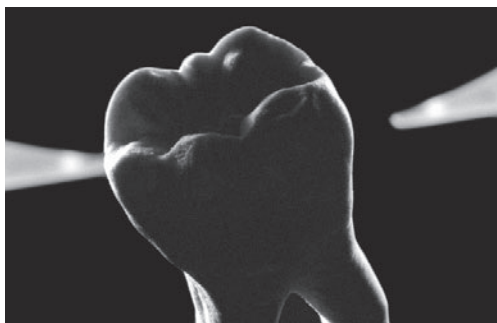
Without the help of these persons, and probably from others that I have forgot to mention, this book would never have been finished.

For this, THANK YOU VERY MUCH TO EVERYBODY!

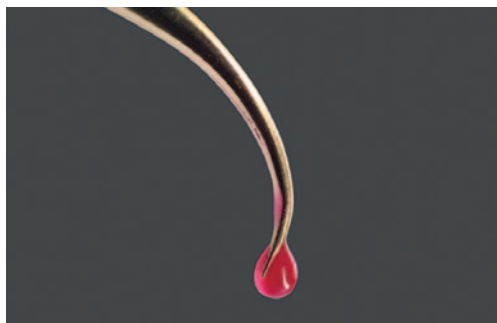
TABLE OF CONTENTS



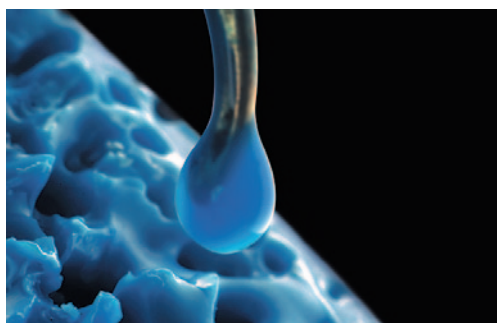
- 1 NOMENCLATURE** 1
Posterior Teeth



- 2 MORPHOLOGIC CHARACTERISTICS** 7
Posterior Teeth




- 3 Wax-up** 27
Training Exercises



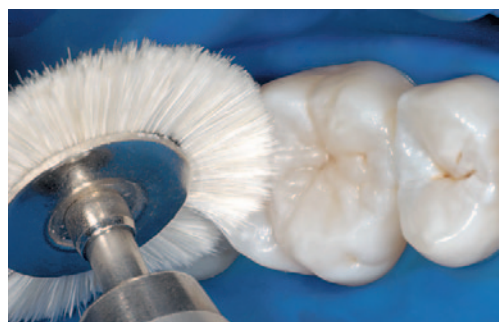- 4 WAX-UP** 33
Maxillary Teeth with Antagonists




- 5 WAX-UP 81
Mandibular Teeth with Antagonists



- 6 WAX-UP 143
Maxillary and Mandibular Teeth



- 7 CLINICAL CASES 243



- 8 CEMENTATION 357
Adhesive Cementation



4 | Chapter

WAX-UP

Maxillary Teeth with Antagonists

In this chapter, wax-up of the maxillary teeth is described according to dental references found in the opposing arch.

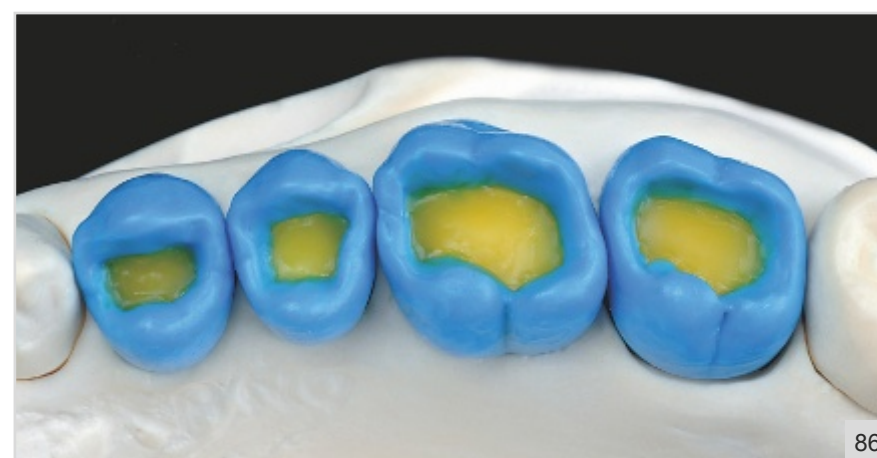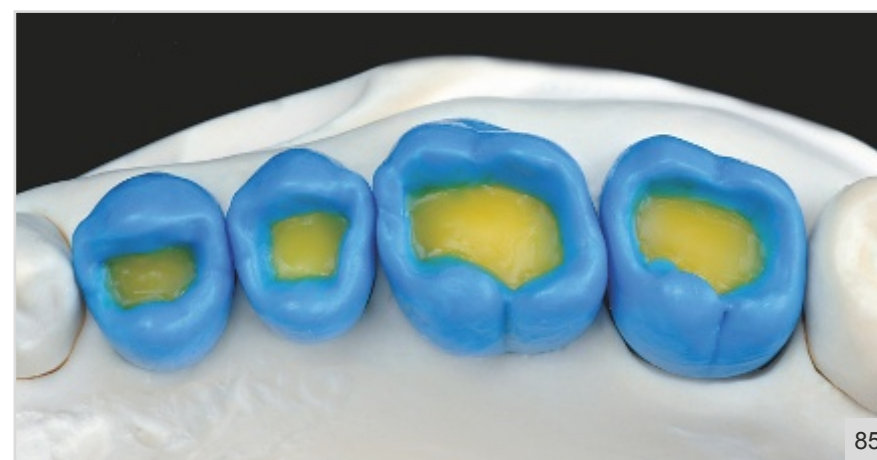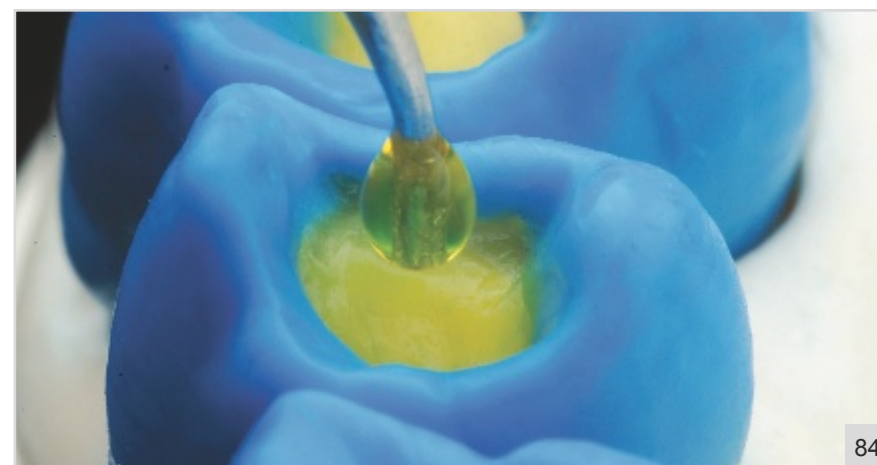


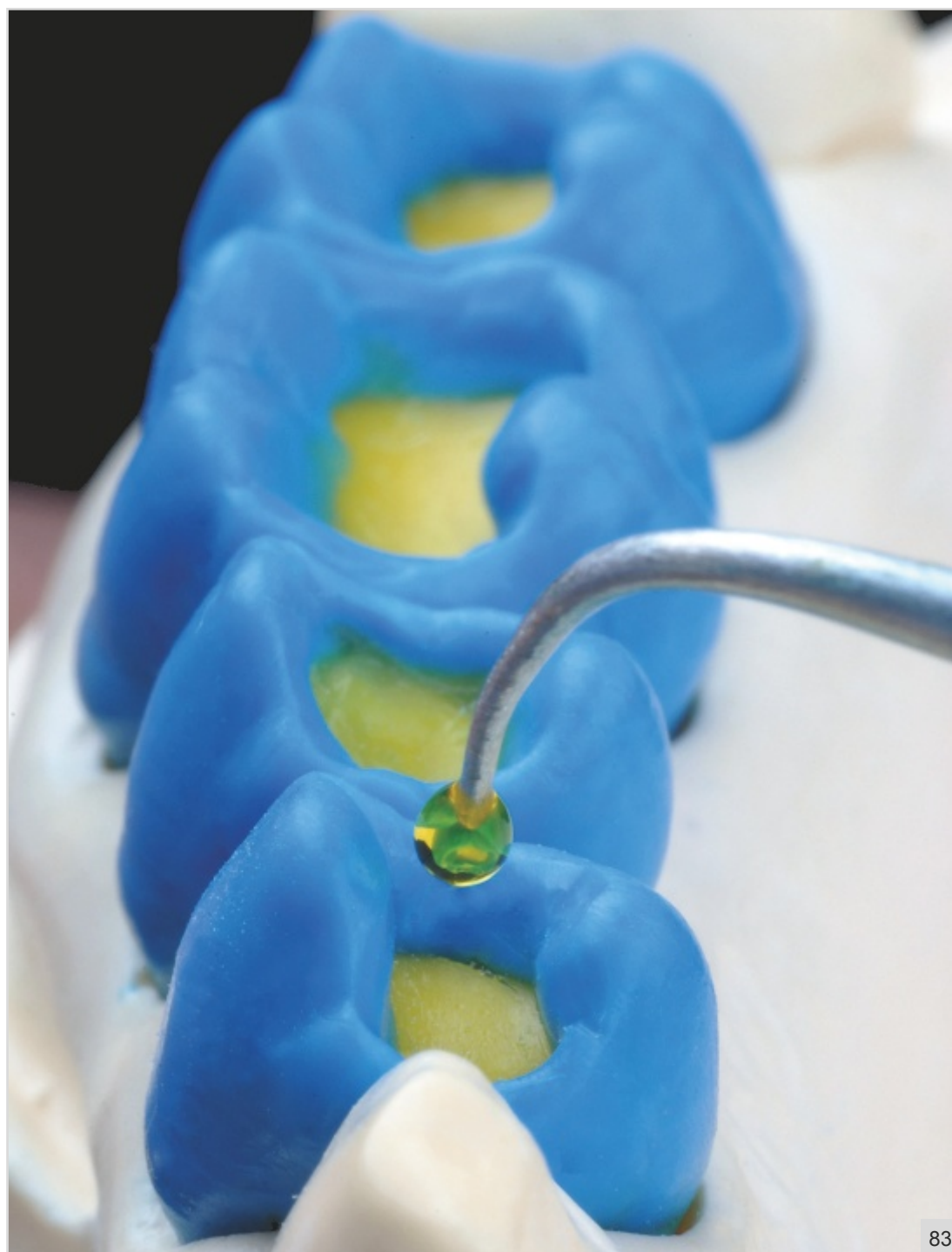Fig 4-83 Before the occlusal surface is constructed, wax must be applied at the cavity floor to establish the fossa pit and groove depths. A useful hint here is to base the depth of the fossa pit on that of adjacent teeth.

Fig 4-84 Close-up view. The wax is placed on the floor of the maxillary second premolar. Extreme caution is necessary here to avoid compromising the surfaces that are already finished.

Fig 4-85 The occlusal aspect of the posterior teeth after establishing of the cavity floor.

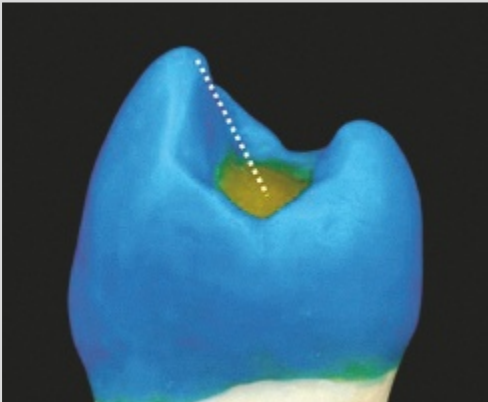
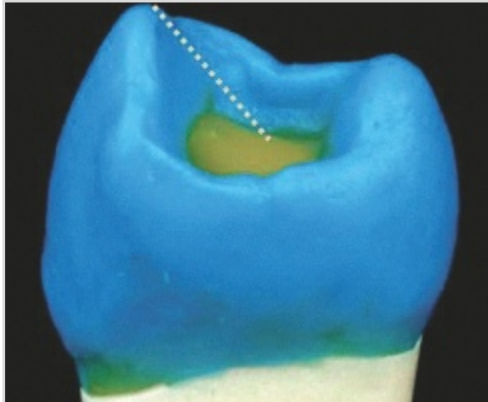
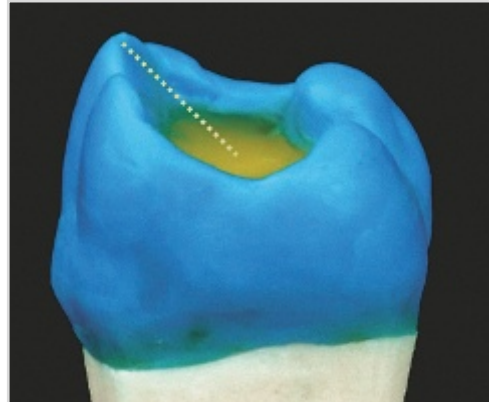
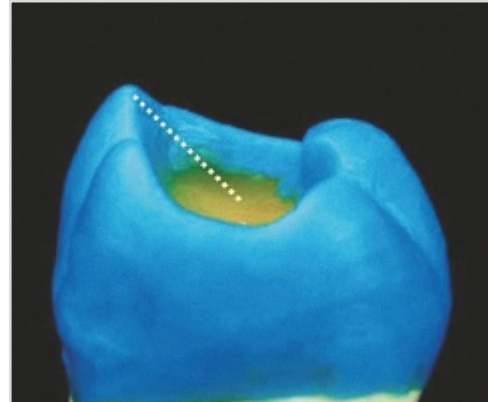
Fig 4-86 It is important to define the longitudinal slopes with a carving instrument in such a way that the occlusal perimeter becomes clearly defined. At this stage, the distances between the buccal and palatal longitudinal slopes of the premolars and molars must be similar, between 6 and 7.6 mm.

OCCLUSAL SURFACE

Groove depth

The distance from the cusp tip to the fossa pit

Table 4-1 Before starting the wax-up of the occlusal surfaces, the cavity floor of the premolars and molars must be constructed by the addition of melted wax in order to standardize the level of fossa and groove depths. Groove depth is measured from the buccal cusp tip to the cavity floor as shown.

Maxillary First Premolar	Maxillary Second Premolar	Maxillary First Molar	Maxillary Second Molar
3.5 mm	3 mm	3 mm	3 mm
			

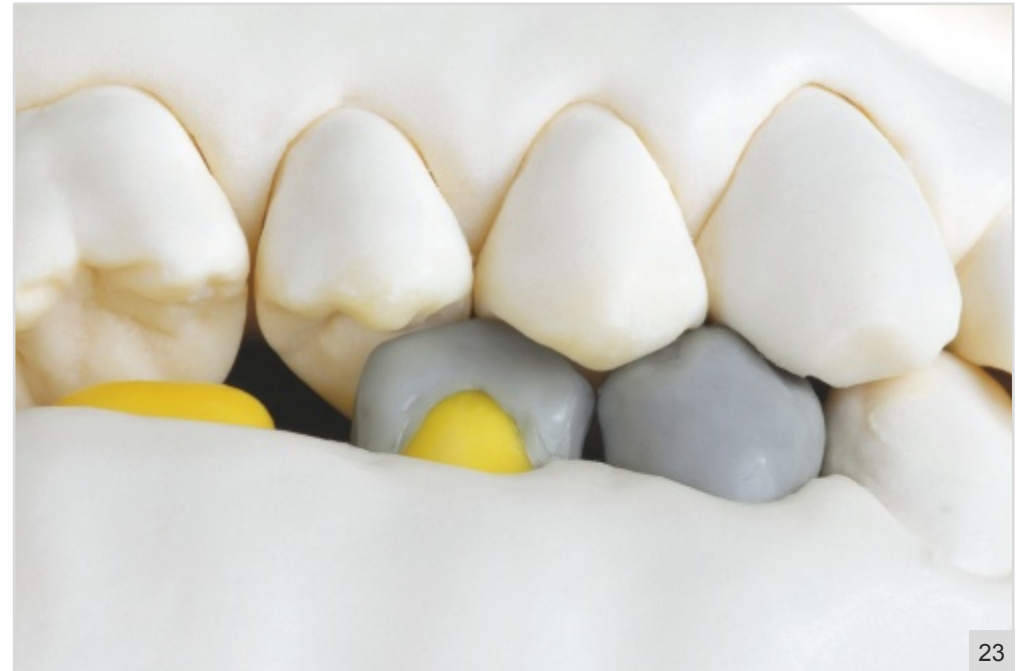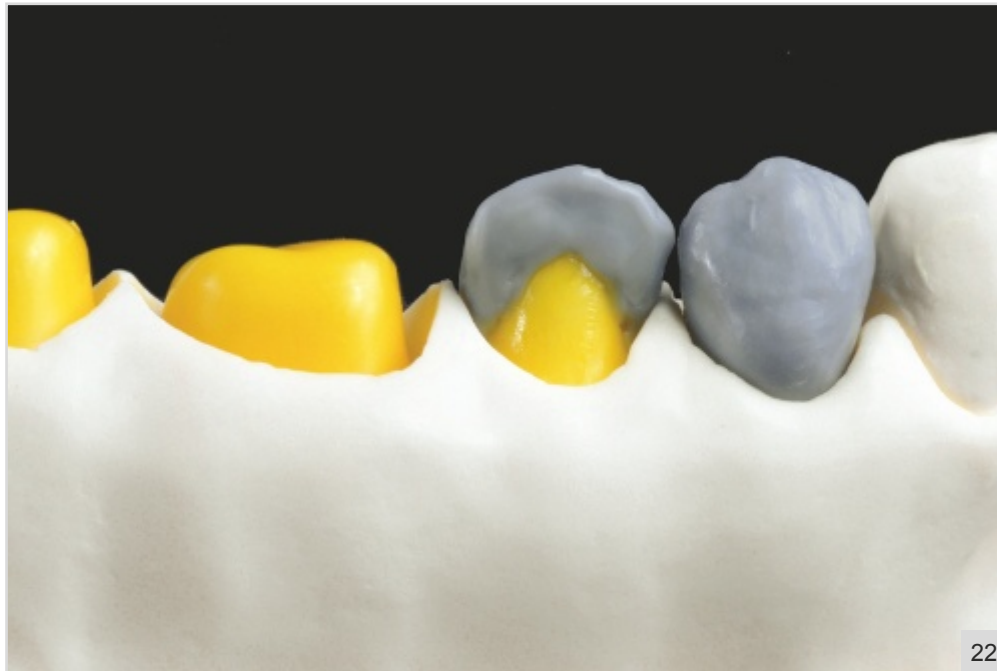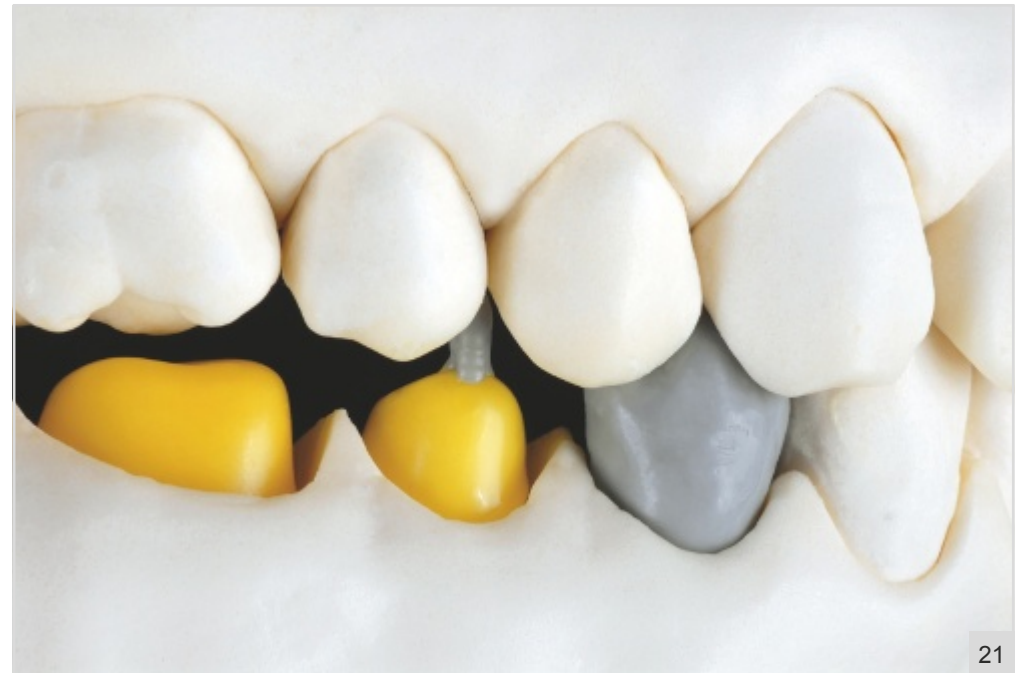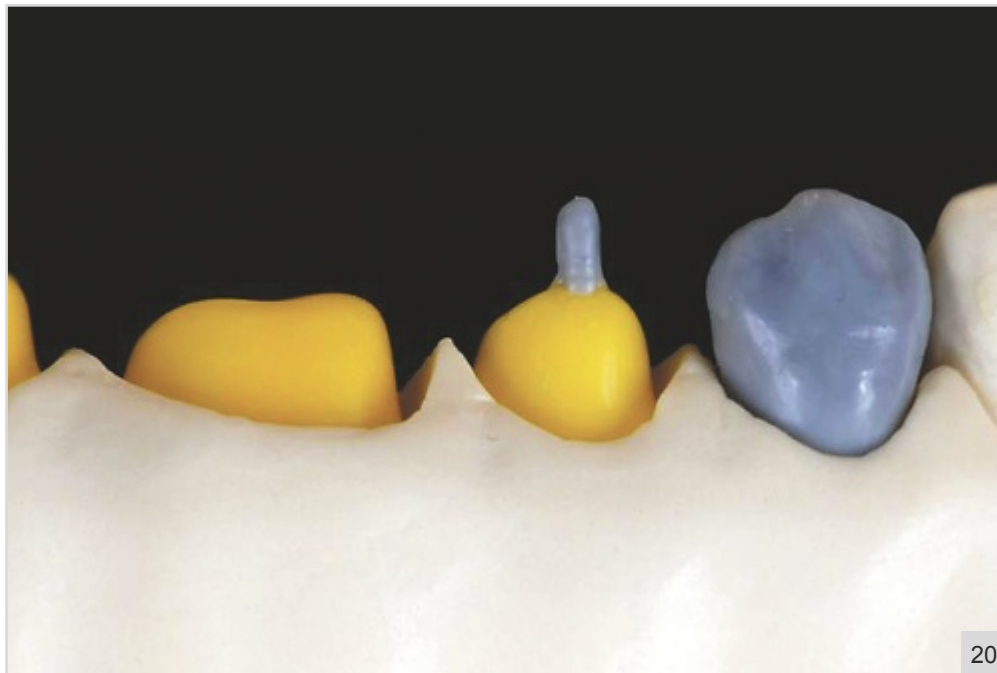


Fig 5-20 The buccal wax cone of the mandibular second premolar, using the opposing teeth as references.

Fig 5-21 This cone is placed between the marginal ridges of the maxillary first and second premolars, without having contact with the antagonists.

Fig 5-22 Next, the mesial and distal longitudinal slopes are positioned.

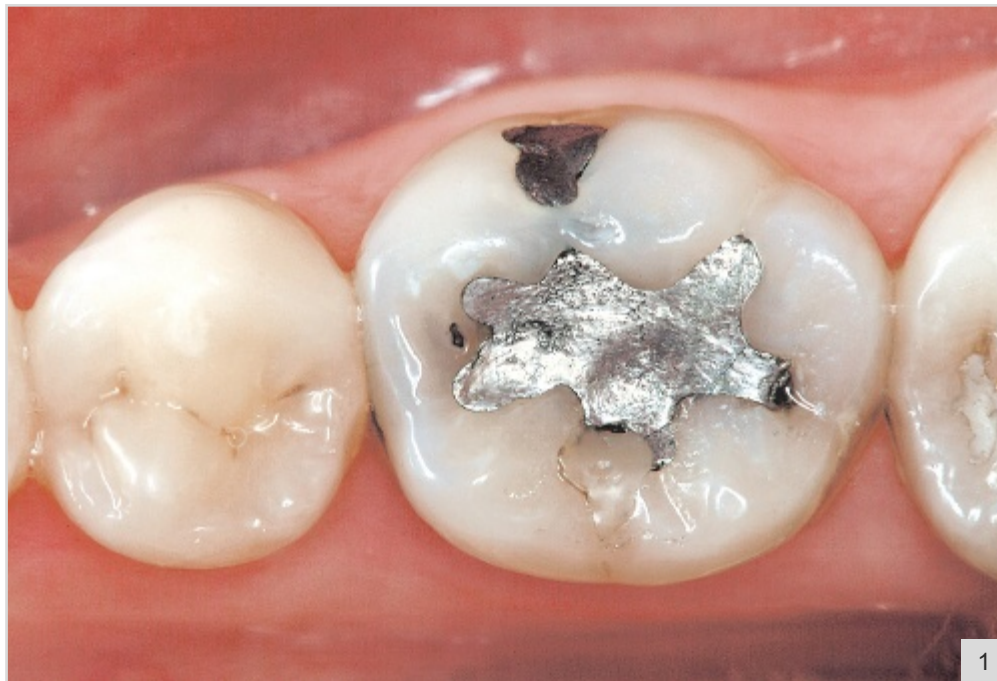
Fig 5-23 The occlusal relationships of the longitudinal slopes with the opposing teeth. Note that the mesial slope should extend from the cone tip to the region of the buccal cusp tip of the maxillary first premolar, while the distal slope should extend from the cone tip to the buccal cusp tip of the maxillary second premolar. At the mesial slope and near the tip, a contact occurs with the distal marginal ridge of the maxillary first premolar, while at the distal ridge a contact occurs with the maxillary second premolar.

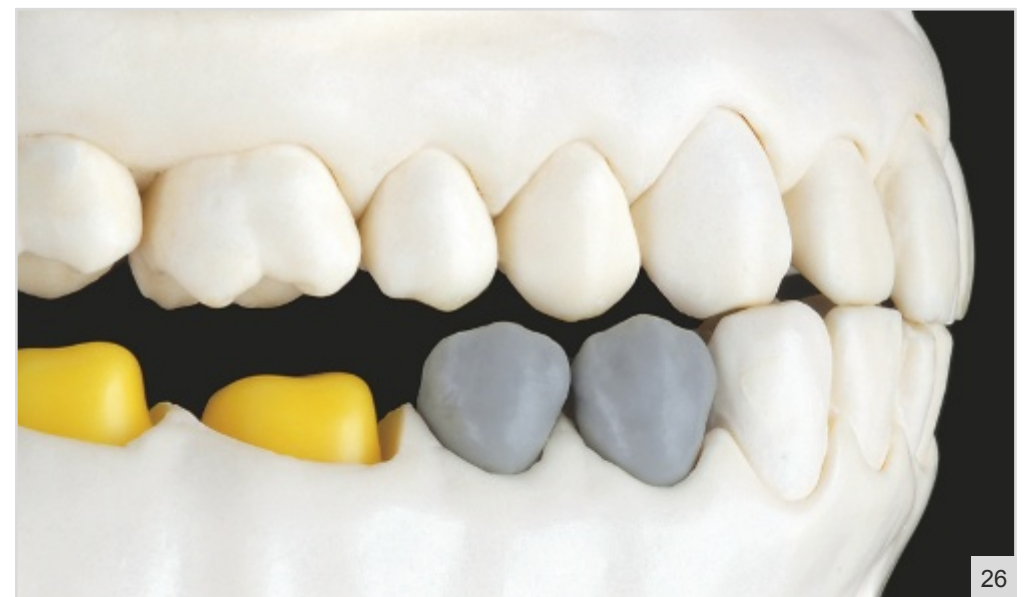
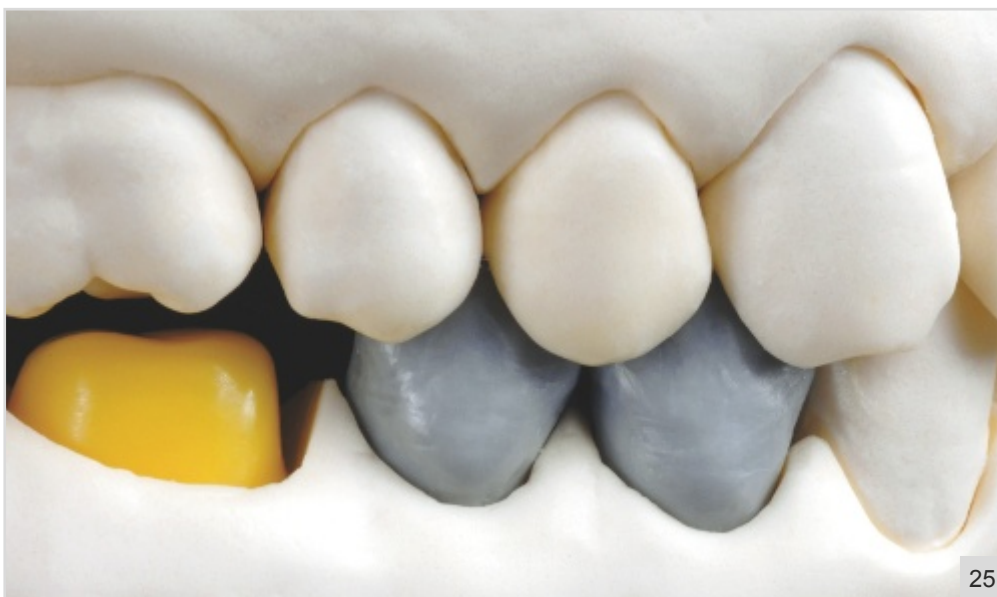
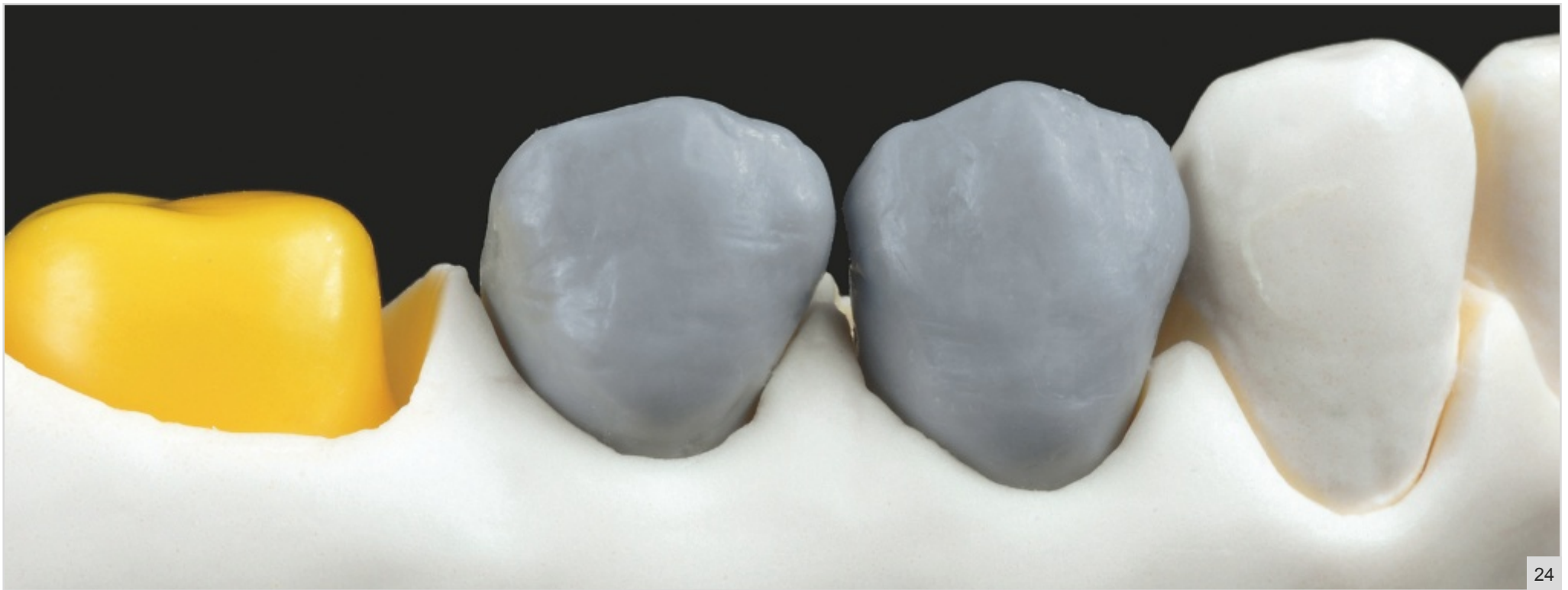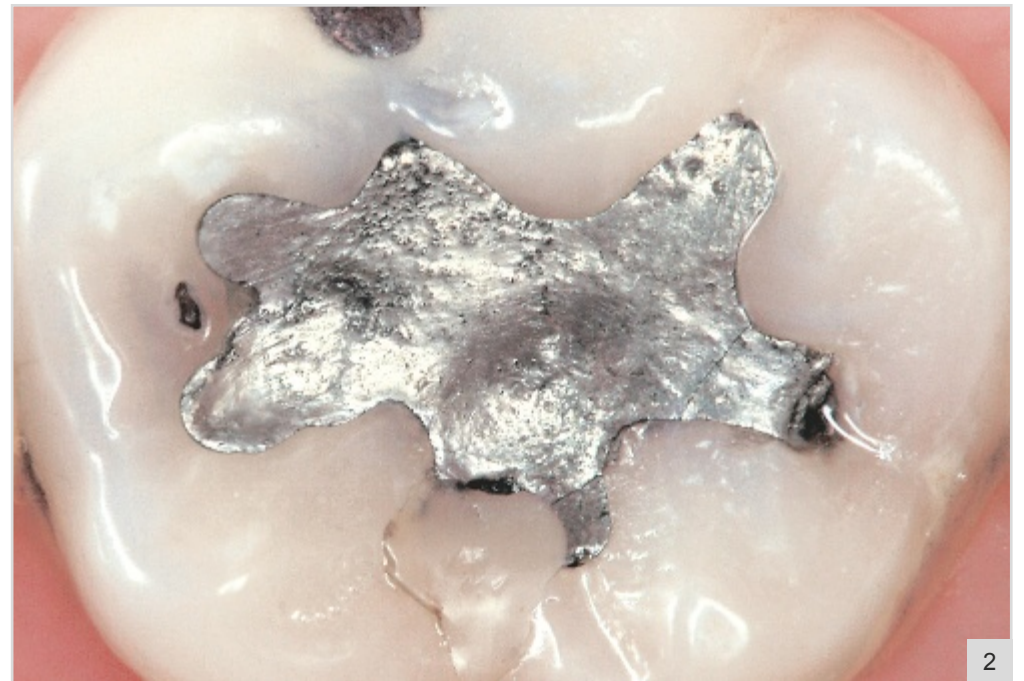Fig 5-24 The finished buccal surface. This surface presents an ovoid format, with a smaller cervical bulge and developmental grooves that are deeper than those of the mandibular first premolar. During the sculpting process, the cervical contours and the cervico-occlusal convexity must be determined according to the preparation finishing lines and the antagonist teeth, respectively.

Fig 5-25 Buccal view of the occlusal relationships between the buccal surfaces of the mandibular premolars and their antagonists.

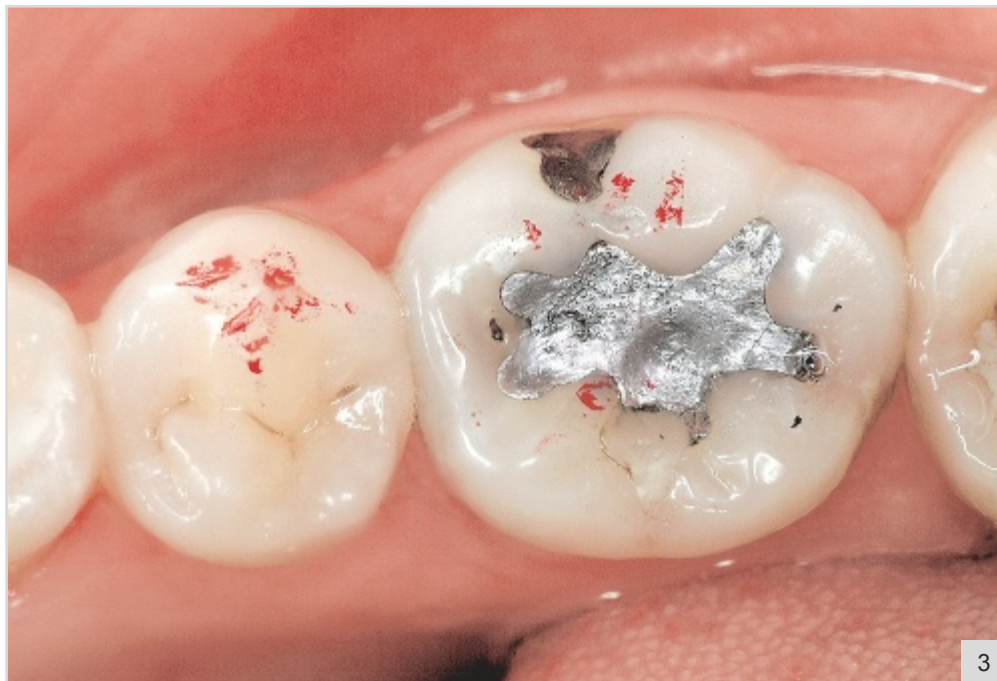Fig 5-26 During excursive movements, there should be no contacts at the buccal surfaces of the premolars because of the disocclusion provided by the anterior teeth.



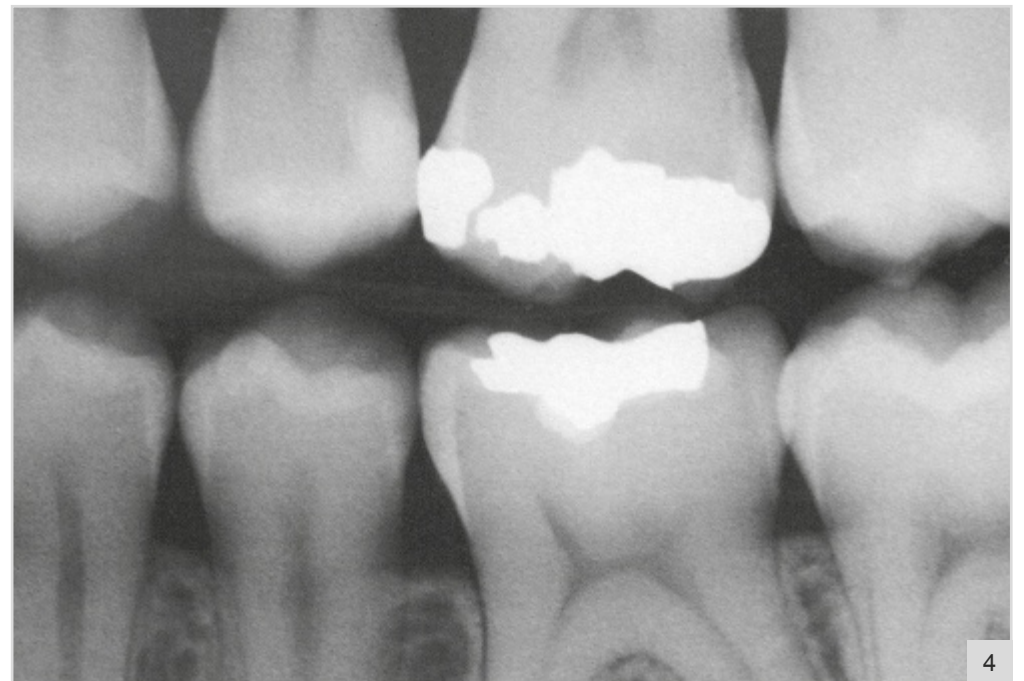1



2



3



4

Clinical Case 1

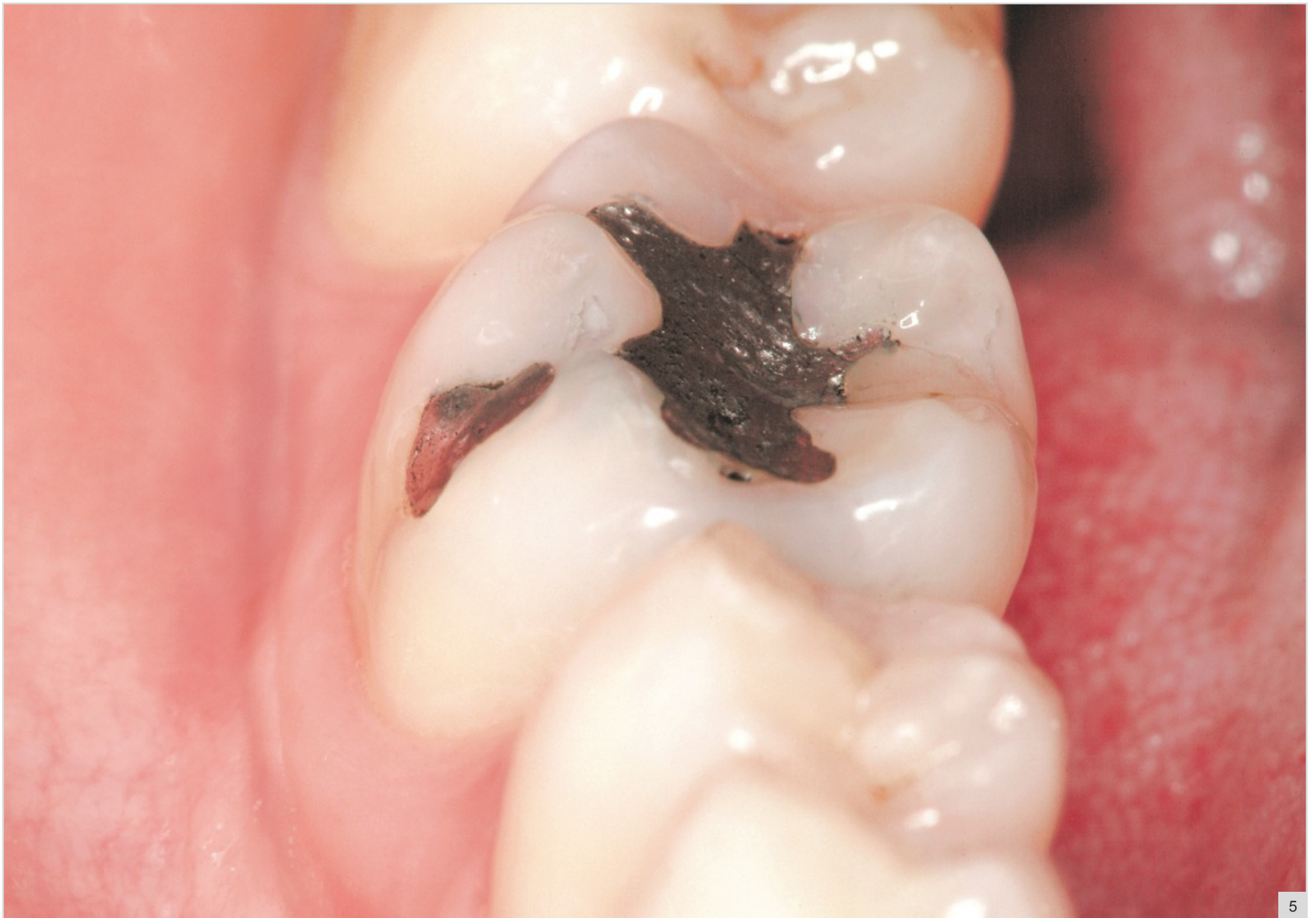Composite Resin Restoration on a Mandibular Posterior Tooth

Fig 7-1 Initial clinical view. The patient's chief complaint was sensitivity to cold stimulus on the mandibular right first molar.

Fig 7-2 Observe the inadequate amalgam filling, with gaps at the tooth-restoration margins, as well as color alterations at the mesial marginal ridge, due to the presence of caries.

Fig 7-3 The occlusal contacts are marked to avoid involvement and extensive restoration at these points.

Fig 7-4 The bitewing radiograph shows that the lesion does not extend to the pulp. The radiolucent area in the mesial region confirms the presence of a caries lesion under the amalgam.



5

Fig 7-5 Initial lateral view before cavity preparation.