
Masahide Tsutsui
Teruko Tsutsui

Comprehensive Dentistry



Quintessence Publishing Ltd.

London, Berlin, Chicago, Tokyo, Barcelona, Istanbul, Milan, Moscow,
New Delhi, Paris, Beijing, Prague, São Paulo, Seoul, and Warsaw

Table of Contents

Foreword 5
Preface 7
Acknowledgments 8

1 **Diagnosis in Comprehensive Dentistry** 9

- Principles of Comprehensive Dentistry 10
- Goal of Dental Care and the Systematization of Science of Occlusion 17
- Comprehensive Diagnosis and Treatment 27
- Inflammation Control and Tooth-Unit Diagnosis 33
- Comprehensive Diagnosis of Dentition-Unit Pathology and Treatment Goals 41
- Comprehensive Diagnosis of Occlusal-Unit Pathology and Treatment Goals 54
- Treatment Goals and Maintenance in Cases with Occlusal Collapse 57

2 **Forces Affecting the Stomatognathic System and Their Control** 77

- Forces in the Stomatognathic System and Occlusal Therapy 78
- Examination and Diagnosis of Stomatognathic Functions 83
- Individual Differences and Jaw Functions 89
- Concepts of Biomechanics and Remodeling 95
- Optimal Mandibular Position 100
- Discovering Functional Movements of the Mandible: Condylar Movements 107
- Discovering Functional Movements of the Mandible: Occlusal Movements 113
- Occlusal Morphology From the Viewpoint of Masticatory Movements 127
- Tight Occlusion Versus Loose Occlusion 131
- Diagnosis and Management of Abfraction 136
- Habits of Circumoral Muscles and Myofunctional Therapy 142
- Relationship of Chewing Habits and Postural Habits to Occlusal Collapse 145
- Pathologic Conditions Derived From Occlusion 157
- Disc Displacement, Arthralgia, and Myalgia 168
- Distortion of Face and Body and Psychologic Stress 190

3 Restorative Tooth Movement 203

Restorative Tooth Movement 204

Restoration of the Periodontal Environment: Mesiodistal and Buccolingual Tooth Movement 215

Restoration of the Periodontal Environment: Vertical Tooth Movement 224

Tooth Movement as a Part of Comprehensive Treatment 232

Tooth Movement in the Presence of Occlusal Collapse 241

4 Inflammation Control and Establishment of Maintainable Periodontal Tissue 253

Diagnosis of Periodontal Diseases and Comprehensive Treatment Planning 254

Objective-Oriented Selection of Periodontal Surgery Procedures 260

Construction of Maintainable Periodontal Tissue 270

Management of Furcation Involvement 276

Vertical Bony Defects and Regenerative Therapy 283

Improvement of Esthetics by Periodontal Plastic Surgery 291

Tissue Reconstruction of Alveolar Ridge Defects 300

Clinical Practice of Periodontal Prosthesis 313

5 Prosthetic Treatment and Improvement of the Oral Environment 333

Prosthetic Treatment as a Replacement Therapy 334

Recovery of a Physiologic Dentogingival Complex and Esthetics 342

Provisional Restoration and the Dentogingival Complex 354

Crown Restoration and Preparation Finish Line 360

Role of Implants in Comprehensive Dentistry 370

Management of Peri-Implant Tissue 394

Functional Recovery and Stabilization of Partially Edentulous Dentitions 406

Treatment Goals for Patients with Multiple Missing Teeth 413

References 440

Foreword

It is with great pleasure and honor that I accepted the invitation to write the foreword to this outstanding text on comprehensive dentistry, which was first published in Japanese. I was so impressed with the case presentations, including the quality of the documentation and illustrated material, that I suggested to Quintessence that the book should be published in English.

In a remarkable paper delivered during the 2003 International Academy of Esthetic Dentistry meeting in Washington, DC, Dr Masahide Tsutsui's lecture was presented in English and astounded dentists from all over the world. To quote Dr Leonard Abrams, "Dr Tsutsui has it all together." This response was typical of those in the audience, which included Drs David Garber, Henry and Maurice Salama, Ronald Goldstein, and Dennis Tarnow, and just about the entire audience was of this caliber. Sadly, with the untimely death of Masahide Tsutsui, this foreword might well serve as a requiem for the life of this outstanding dental practitioner, teacher, human being, and the co-author of this beautiful text.

As indicated by the title *Comprehensive Dentistry*, the Tsutsuis have formulated an approach to the study and practice of the art and science of dentistry that takes into consideration an understanding of all aspects of the many parts of the stomatognathic system as well their relationship to the whole body. For this approach, they started viewing their patients as individuals who may be quite different from each other and, therefore, "statistically insignificant." Hence, they present a significant series of anecdotal (ie, single case) histories that were diagnosed based on careful, critically strict criteria. Their therapeutic intervention with these patients produced respectively similar results, giving birth to evidence-based information. In addition to the exquisite quality of Dr Masahide Tsutsui's restorative dentistry and periodontal therapy as well as Dr Teruko Tsutsui's imaginative and exacting approach to orthodontic diagnosis and therapy, one can be sure of the consistency of their approach to the clinical problem.

The Tsutsuis take us through the complex arena of traditional problems associated with the era of periodontal prosthesis and the increased attention to esthetics, particularly as it relates to the dentogingival complex. These problems presented difficulties when dealing with the restoration of the natural dentition; they presented even more difficulties when dealing with the restoration of anterior implant abutments. Dr Tsutsui competently managed this transition along with the intelligent integration of osseointegrated implants into his treatment plan. I can only give this book my highest recommendation, and I congratulate and thank the publisher for recognizing its need to be translated into English.

Morton Amsterdam, DDS, ScD

Professor Emeritus of Periodontics and Periodontal Prosthesis
Norman Vine Professor of Restorative Dentistry
University of Pennsylvania
School of Dental Medicine

Preface

This book introduces the most important concept in our clinical practice: control of inflammation and forces. Control of inflammation is relatively simple; inflammation can be diagnosed, and its cause and consequences are related to each other. On the other hand, forces are not easy to deal with because forces are invisible.

Clinical incorporation of treatment of forces can be assumed to occur if inflammation is properly controlled and basic procedures are routinely conducted with high precision. The result of these forces is manifested in the “shape” of a total oral system comprising the individual tooth, the dentition, and the arches. To precisely determine change with the passage of time, diagnostic tools such as facial and clinical photographs, probing data, full-mouth radiographs, temporomandibular joint radiographs, cephalograms, and study casts must be available. Adding an analysis of functional jaw movements to this diagnostic material helps to determine what forces will affect the patient.

The decisive role of the clinician comes into play in the thorough examination and analysis of a patient’s intraoral and facial conditions, as well as the body as a whole. Review of all the gathered data will allow a better understanding of how forces are incorporated in the patient’s overall dental health.

Principles of these approaches to forces are discussed in chapter 2 of this book. The format of this chapter is different from that of other chapters. Many readers may find this chapter less approachable and more difficult to understand. We propose some hypotheses, which are not included in commonly accepted theories, and have tried to prove them through clinical cases. Because clinical practices by their nature do not suit quantitative evaluations nicely, an indisputable demonstration is impossible. Still, the concept of force control described in chapter 2 is the backbone of our current clinical practice.

The objective of our clinical practice is not to prove these hypotheses. In our clinical practice, we are confronted with the results of these hypotheses every day. Even if we were not advocating these hypotheses, we see them in practice every day. We wish to obtain stable treatment results, to maintain beautiful gingiva, to restore natural bone level and a fine arch shape, and to achieve an easily maintainable dentition in a healthy and comfortable way. The hypotheses are continually examined thoroughly as they are routinely utilized in our practice.

In the late 1980s, we started to consider introducing our treatment concepts to others. More than 10 years passed while we developed this project. One difficulty was our ability to articulate our ideas clearly. Incorporation of new technologies into our practice was also a stumbling block to completing this work.

Fortunately, in cooperation with Mr Hidetoshi Akimoto, Editorial House AKI, Ltd, who is a longtime sympathizer and excellent editor, we brought our thoughts together in this book. A large number of patients have taught and encouraged us, helping us to realize our goal. We would like to thank all of those patients, and we sincerely hope this book will be of some help to our colleagues in their daily practice.

Acknowledgments

It has been 27 years since we opened our private practice in Kitakyushu, Japan. We were fortunate to have graduated from dental school when the Japanese dental academy was in its growth period. Flooded with information, we incorporated without hesitation any idea that was said to be “good,” and these choices resulted in our present clinical practices.

In our practice, Masahide is responsible for endodontics, periodontics, prosthetics, and implantology, while Teruko is responsible for occlusion, orthodontics, and pedodontics. Our fundamental policy is that both of us should be able to critically evaluate and perform the basics of clinical dentistry, in addition to which we each have our own areas of expertise.

We owe what we are today to our many patients, our respected teachers at the university, our honored mentors in clinical practice, senior clinicians in our study group, colleagues in our community, and clinicians who are students of our Tsutsui Study Club, which started as a lecture course on orthodontics in 1988 and later developed into a course that covers comprehensive dentistry. Because students who complete the lecture course of this study club are allowed to participate in the course as observers, for life, we as instructors always have to be conscious of the graduates' observations. Their questions about how our thinking has advanced or what has happened within a specific clinical case have become the source of our progress.

It is customary in books to list the names of mentors who taught the authors, senior clinicians who influenced the authors, and colleagues who encouraged the authors. Our list of names would be long. Excuse us for refraining from giving the names here, since there are too many to be specific. If asked from whom we have learned the most, starting from the most fundamental ethical issues as health care professionals to clinical issues, we would say that we owe it to our patients. Without fail, it is our patients who have taught us the most.

We would like to thank our staff members who support us in our daily practice. We will continue in our endeavor to improve the health of our patients while searching for further advances in clinical practice. Both of us are grateful for being given the opportunity to work with a wonderful partner within our profession.

Last, but not least, we would like to express our gratitude to Mr Ikko Sasaki of Quintessence Publishing Co, Ltd, who published this book after patiently watching over us as we completed this seemingly endless task.

Subgingival contour

Tooth reduction in the preparation and restoration contour should be adjusted, depending on the progress of the periodontal disease, region, tooth axis inclination, root proximity, and gingival conditions. In regions with advanced periodontal disease, the thickness of the gingiva is increased and the interdental space is enlarged, changing the gingival contour significantly compared to a healthy condition. Consequently, the subgingival contour of a prosthesis has to be adjusted according to local conditions (Fig 4-38). When the tooth is inclined lingually, there is an increase in the thickness of the labial gingiva, and sufficient subgingival contour has to be provided to the labial side. In a case with close root proximity, the required space has to be assured in the interdental area through sufficient tooth reduction and controlled contour.

Figure 4-39 and Case 4-2 demonstrate the benefits of careful gingival preparation before prosthetic intervention.

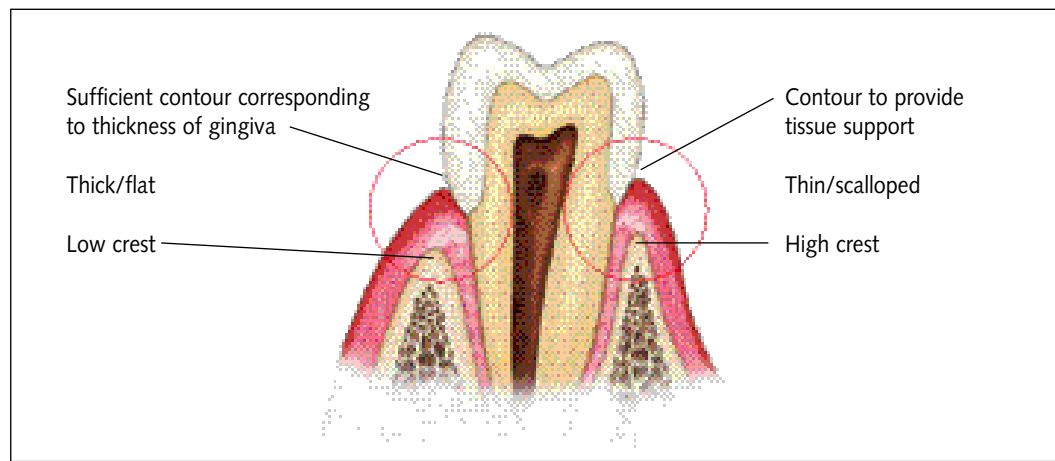
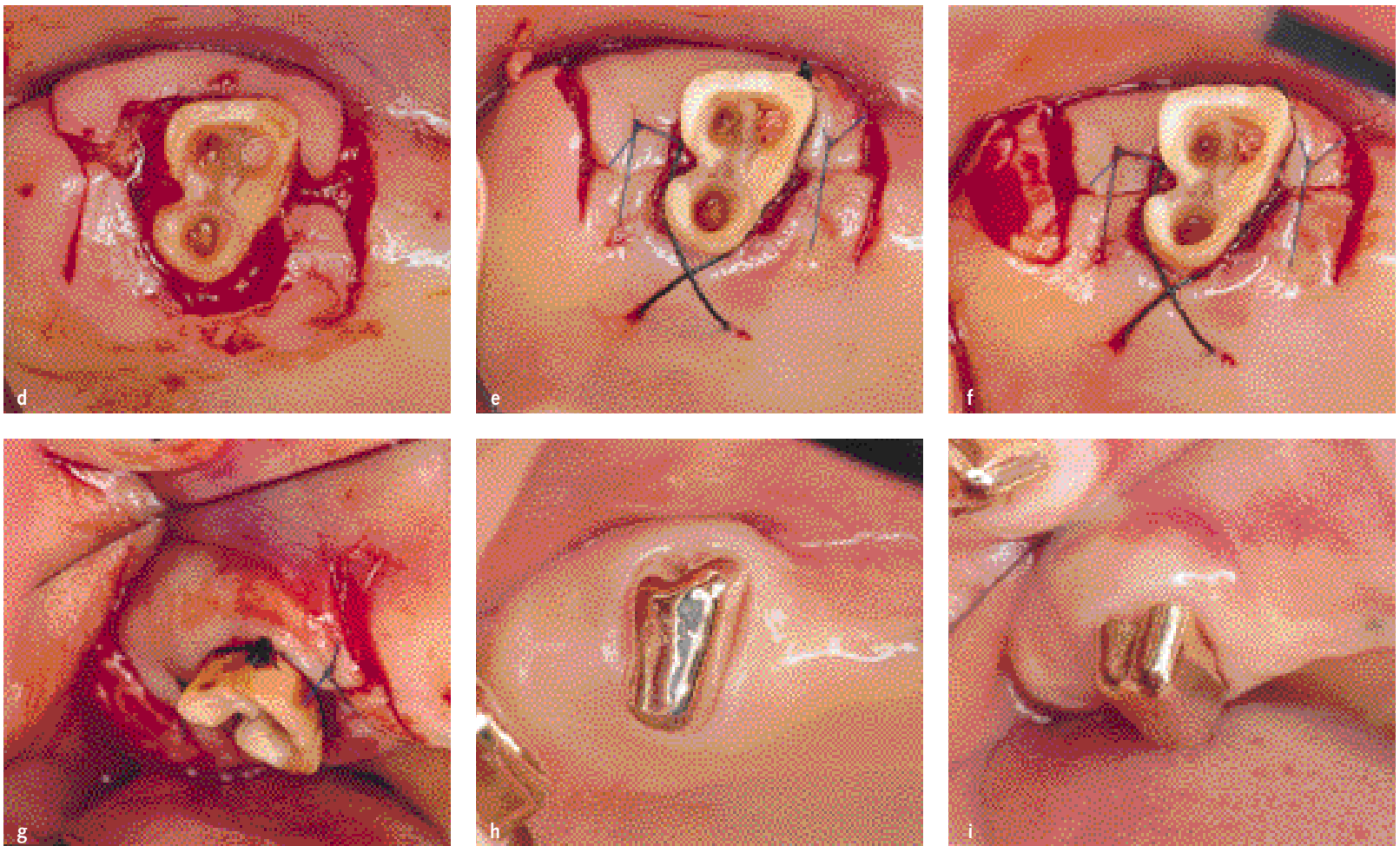


Fig 4-38 Subgingival contouring of the prosthesis is said to have a role in proper support of the gingiva. Relatively strong contours are needed when the gingiva is thick. Consideration should be also given to the inclination of the tooth axis, tooth type, and buccolingual or proximal surface differences. Gingiva becomes thicker in periodontal tissue with attachment loss, for which a relatively stronger contour is required.

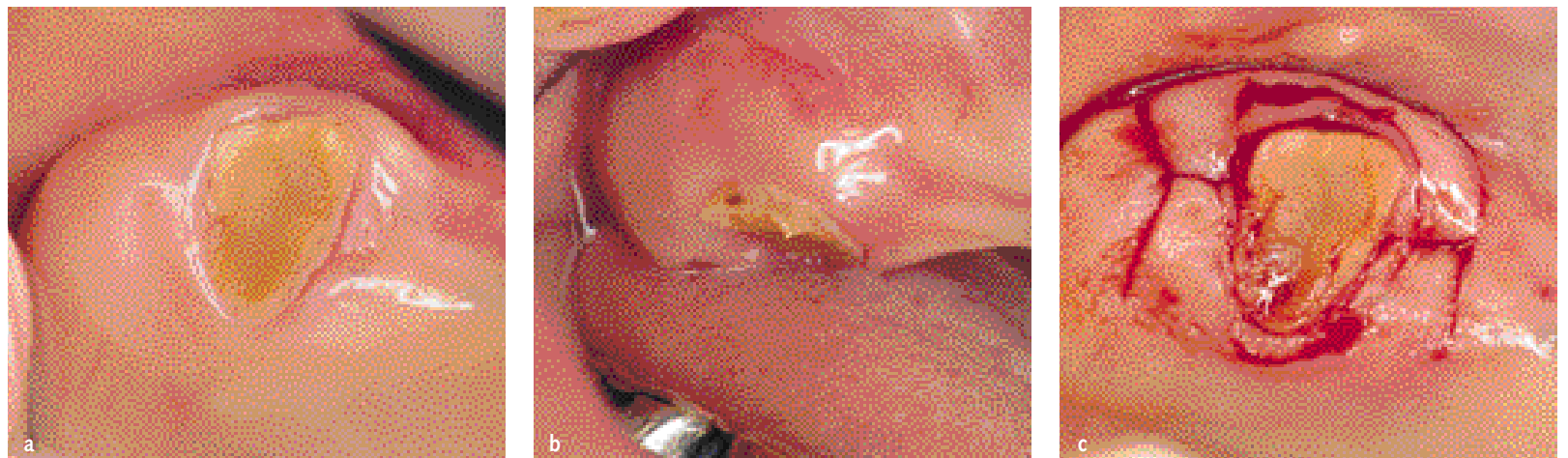

Fig 4-39 Clinical crown lengthening for an isolated residual root of a maxillary molar. (a and b) Residual root of the maxillary right second molar after root canal treatment. (c) An inverse bevel incision and vertical incision are made symmetrically.



(d) It is important to elevate a full-thickness flap carefully without damaging the periosteum. (e) The connective tissue is dissected, leaving a uniform thickness of the gingiva on the buccal and palatal sides, and removed as one piece to allow bone resectioning. Symmetric simple sutures are made without excessive tension, and cross sutures are made on the palatal aspect. (f and g) Excess gingiva on the palatal aspect is resected to complete the procedure. (h and i) Photographs taken 1 year postsurgery.

Case 4-2 Resective therapy using a partial-thickness flap

Patient: 61 years old at the time of first visit in 1997. With secondary dental caries, malocclusion caused by restorations, and poorly treated root canals after pulp-ectomies, this patient seemed to have iatrogenic prob-

lems. The conditions almost caused a collapse of the occlusion. The patient exhibited a generally disturbed occlusal plane, deformed dental arches, and tooth migration. Here focus is given to the treatment of the

subgingival dental caries of the mandibular right first molar, which exhibited a narrow vestibule and limited attached gingiva (Figs 4-40 to 4-43).

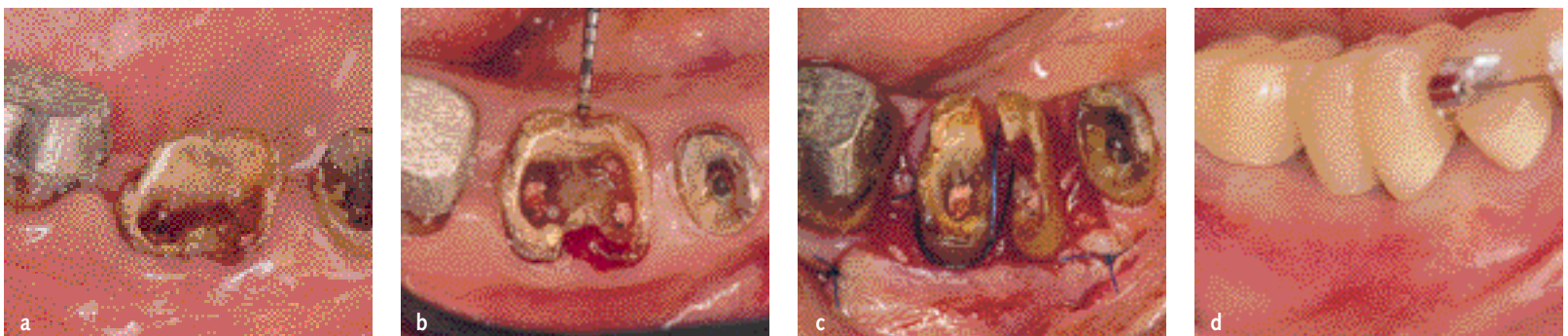


Fig 4-40 Treatment of subgingival dental caries of the mandibular right first molar. (a and b) Photographs taken 1 year 6 months after the first visit. In conjunction with plaque control, a temporary root canal filling is placed. A provisional restoration is placed and orthodontic tooth movement is performed, until the patient is ready for the final stage of treatment. The mandibular right first molar has a class III furcation involvement with subgingival caries and only 1 to 2 mm of attached gingiva. (c) A sulcular incision is made to form a full-partial-thickness flap without loss of the attached gingiva, and the flap is apically repositioned. After osseous surgery, the tooth is hemisected. (d) After a 3-month healing period for the periodontal tissue, orthodontic treatment was restarted. (Photograph taken 6 months after surgery.)

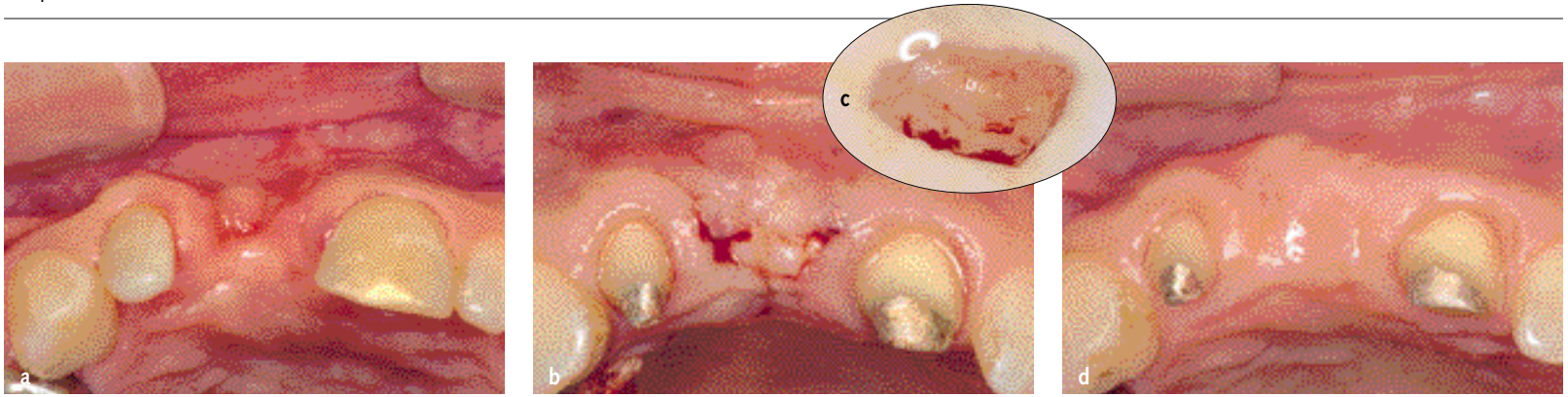


Fig 4-138 Augmentation of the alveolar ridge defects. (a) A significant concavity exists on the buccal aspect of the ridge. (b and c) A large connective tissue graft (6 mm wide × 12 mm long) is harvested from the palate and subepithelially grafted. (d) Photograph taken 4 months postsurgery. The buccal concavity has improved considerably.

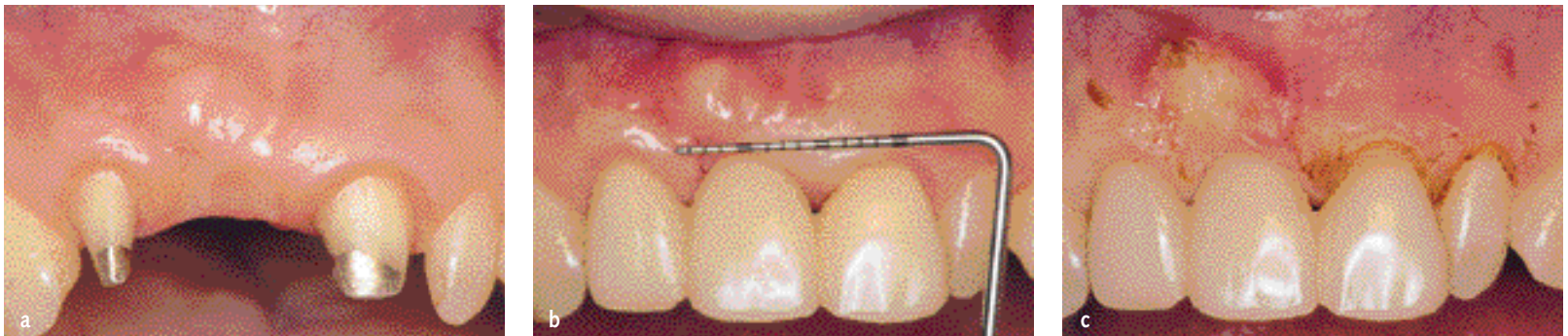

Fig 4-139 Aligning the gingival margin. (a) Photograph taken 4 months postsurgery. The gingival margin is irregular. (b and c) The gingiva is leveled by electrosurgery.

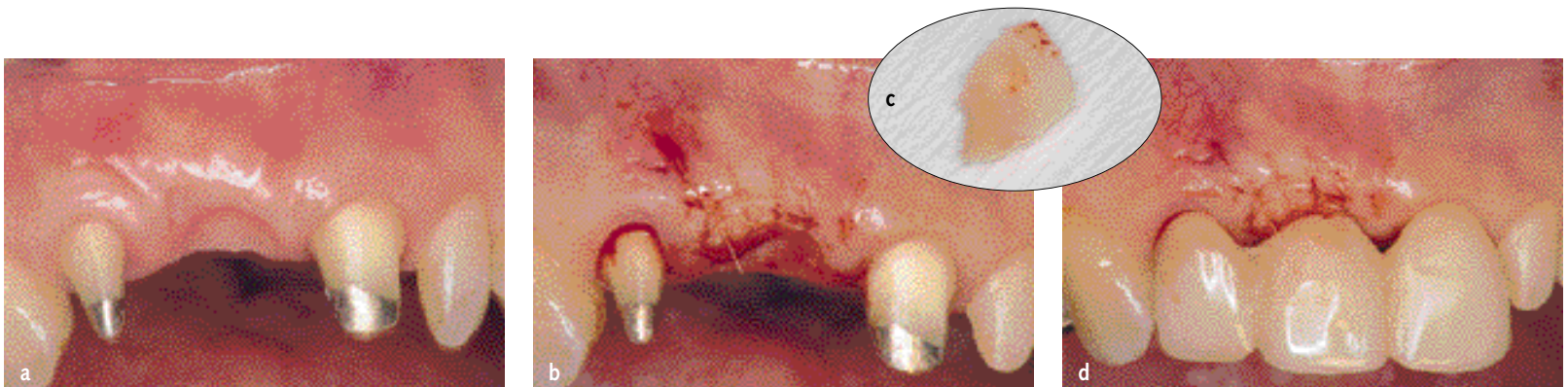


Fig 4-140 Second augmentation. (a) Photograph taken 6 months after augmentation of the alveolar ridge defects. (b) Compared to the left side, the interdental papilla between the maxillary right lateral incisor and central incisor remains flat, with an asymmetric gingiva. There is also a concern about the concavity between the maxillary right lateral and central incisors. (c and d) An envelope is formed to communicate with the mesial sulcus of the maxillary right lateral incisor. A wedge-shaped connective tissue graft is harvested from the area distal to the last molar and grafted to the mesial aspect for regeneration of the interdental papilla.

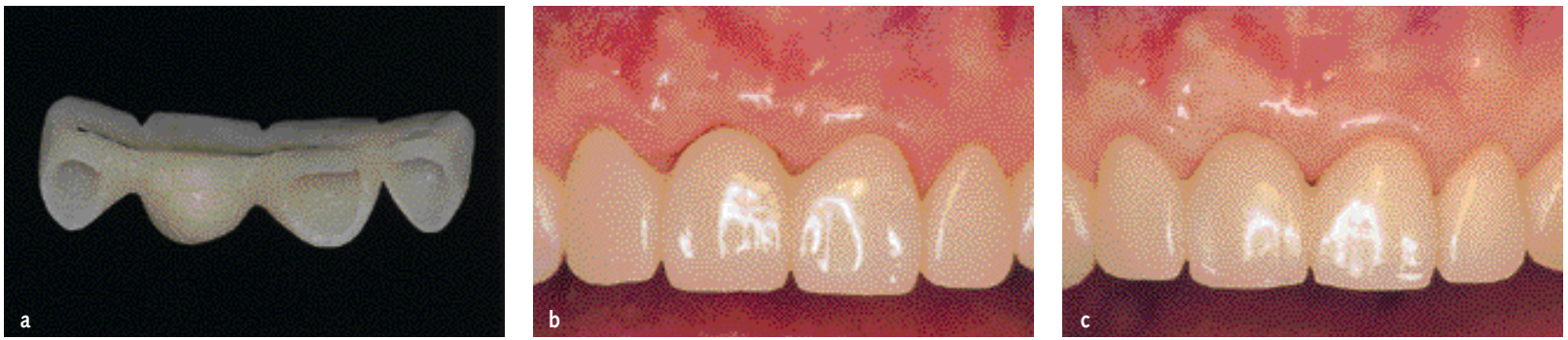

Fig 4-141 Ovate pontic. (a) A provisional pontic is fabricated to be symmetric to the maxillary left central incisor. (b) At each visit, self-curing acrylic resin is added to the pontic to further adjust the pontic shape. (c) The final provisional restoration. Correct gingival margins and interdental papillae have been obtained.

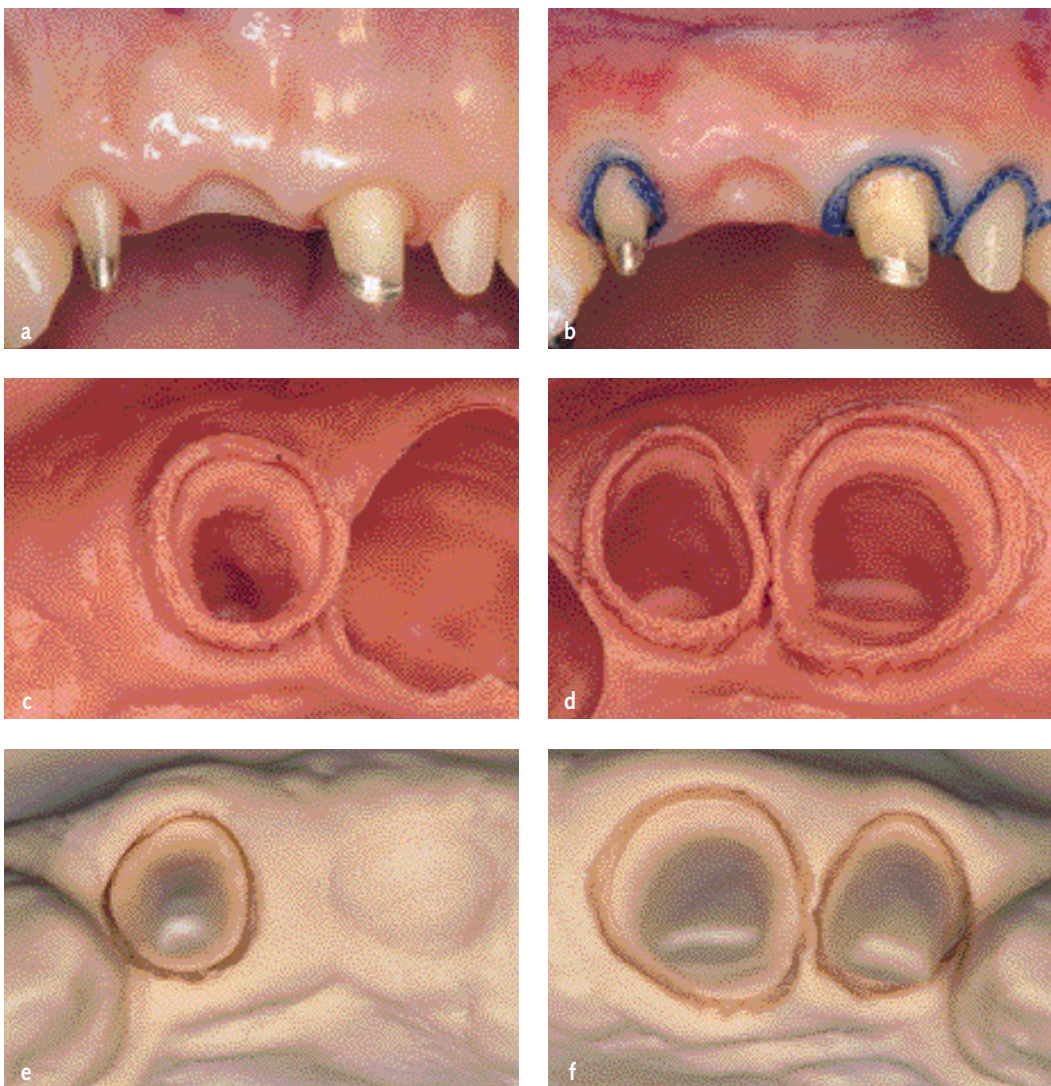


Fig 4-142 Impression taking for final prostheses. (a) Ovate pontic area after preparation. (b) Gingival retraction is completed carefully. To avoid damage to the gingiva, retraction cord must not be left in place longer than 10 minutes. (c to f) HIT impression showing clear preparation margins. (g) Gingival surface of the ovate pontic.